

Cavitary Pulmonary Disease

L. Beth Gadkowski and Jason E. Stout*

Division of Infectious Diseases and International Health, Duke University Medical Center, Durham, North Carolina

INTRODUCTION	305
WHAT MAKES A CAVITY?	306
Pathophysiology of Cavities.....	306
CHEST IMAGING TO DETECT CAVITIES	306
Characteristics of Cavities Used for Differential Diagnosis	306
NONINFECTIOUS DISEASES ASSOCIATED WITH LUNG CAVITIES	307
Malignancies.....	307
Rheumatologic Diseases.....	307
Miscellaneous Diseases Associated with Cavities	308
INFECTIONS ASSOCIATED WITH LUNG CAVITIES	309
Common Bacterial Infections.....	309
Necrotizing pneumonias and lung abscesses	309
Septic pulmonary emboli	310
Uncommon Bacterial Infections	311
Actinomycosis	311
<i>Nocardia</i>	311
Melioidosis.....	311
<i>Rhodococcus</i>	312
Mycobacterial Infections.....	312
<i>Mycobacterium tuberculosis</i>	312
Nontuberculous mycobacteria	312
(i) <i>Mycobacterium avium</i> complex	313
(ii) <i>Mycobacterium kansasii</i>	314
(iii) <i>Mycobacterium mageritense</i>	314
(iv) <i>Mycobacterium xenopi</i>	315
(v) Rapidly growing mycobacteria	315
Fungal Infections	315
Aspergillosis.....	315
Zygomycosis.....	316
Histoplasmosis	317
Blastomycosis	318
Coccidioidomycosis	318
Paracoccidioidomycosis	318
Cryptococcosis	319
<i>Penicillium</i>	319
<i>Pneumocystis jirovecii</i>	319
Miscellaneous fungi.....	320
Parasites.....	320
<i>Echinococcus</i>	320
Paragonimiasis.....	320
CAVITARY LUNG DISEASE IN SPECIFIC HOSTS	323
Human Immunodeficiency Virus	323
Hematologic Malignancy and Transplantation	324
CONCLUSIONS	325
ACKNOWLEDGMENTS	325
REFERENCES	325

INTRODUCTION

Cavities are frequent manifestations of a wide variety of pathological processes involving the lung. The presence of a cavity helps the

clinician to focus the diagnostic evaluation, as some diseases are more commonly associated with cavities than others. In the case of infectious diseases, cavitation represents the outcome of complex interactions between host and pathogen. The focus of this review is to assist the clinician and clinical microbiologist in the evaluation of patients presenting with pulmonary cavities. We will broadly review the differential diagnosis of pulmonary cavities and specifically examine host-pathogen interactions associated with cavitation.

* Corresponding author. Mailing address: Division of Infectious Diseases and International Health, Box 3306, Duke University Medical Center, Durham, NC 27710. Phone: (919) 684-3279. Fax: (919) 681-7494. E-mail: stout002@mc.duke.edu.

WHAT MAKES A CAVITY?

A cavity has been defined in the radiology literature as (pathologically) “a gas-filled space within a zone of pulmonary consolidation or within a mass or nodule, produced by the expulsion of a necrotic part of the lesion via the bronchial tree” and (radiographically) “a lucency within a zone of pulmonary consolidation, a mass, or a nodule; hence, a lucent area within the lung that may or may not contain a fluid level and that is surrounded by a wall, usually of varied thickness” (368). In theory, one would like to distinguish a cavity from other air- or fluid-filled lung structures with different pathophysiologies, but in practice, this is not always possible. Some have tried to make this distinction by defining cysts as being air-containing spaces surrounded by a thin (4 mm or less) wall and cavities as being air-containing spaces with walls that are at least 5 mm thick (322). Unfortunately, considerable overlap in etiology and pathophysiology exists between these two categories. For example, bronchogenic cysts are benign developmental abnormalities of the lung that usually appear to be homogeneous masses with the density of water. However, bronchogenic cysts may contain air and have been confused with more typically cavitory lesions such as lung abscesses, fungal infections, or tuberculosis (7). Other air-filled pulmonary lesions such as emphysematous bullae may also be radiographically indistinguishable from cavities (212). Therefore, for purposes of this discussion, a cavity will be defined as any radiographic opacity with an internal area of lucency, regardless of wall thickness.

Pathophysiology of Cavities

A cavity is the result of any of a number of pathological processes including suppurative necrosis (e.g., pyogenic lung abscess), caseous necrosis (e.g., tuberculosis), ischemic necrosis (e.g., pulmonary infarction), cystic dilatation of lung structures (e.g., ball valve obstruction and *Pneumocystis pneumonia*), or displacement of lung tissue by cystic structures (e.g., *Echinococcus*) (204). In addition, malignant processes may cavitate because of treatment-related necrosis, internal cyst formation, or internal desquamation of tumor cells with subsequent liquefaction (92, 251). The likelihood that a given process will cavitate depends upon both host factors and the nature of the underlying pathogenic process. The prevalence of cavities among persons with a given process varies widely. In general, certain processes tend to form cavities more commonly than others. For example, *Mycobacterium tuberculosis* generally has the highest prevalence of cavities among persons with pulmonary disease of any infection, probably because this pathogen causes extensive caseous necrosis. In the case of *M. tuberculosis*, the tendency to form cavities is clearly advantageous to the propagation of the organism because cavities contain large numbers of organisms, which can then be efficiently aerosolized and transmitted to other susceptible hosts (129, 347). Other pathogens, such as *Klebsiella pneumoniae*, are associated with extensive pyogenic lung necrosis and frequent cavitation (254). This organism is also disproportionately represented among cases of pulmonary gangrene, in which there is extensive pulmonary necrosis and infarction, suggesting that the organism possesses pathogenic determinants that are more likely to lead to pulmonary necrosis and cavitation than other

common causes of pulmonary infection, such as *Streptococcus pneumoniae* (296). The predilection to form necrotic cavities may be due to the priming of the inflammatory response by the concurrent aspiration of stomach acid (372) or factors specific to the organism, such as endotoxin (348). Unfortunately, there is no single common factor that differentiates organisms that are frequently associated with pulmonary cavitation from organisms that are rarely associated with pulmonary cavitation. However, as a general rule, organisms that cause subacute or chronic pulmonary infections (e.g., mycobacteria and fungi) seem to be more frequently associated with cavities than organisms that cause acute pulmonary infections (e.g., viruses and *S. pneumoniae*). This rule has many exceptions (e.g., necrotizing pneumonias associated with *Staphylococcus aureus* and *K. pneumoniae*).

CHEST IMAGING TO DETECT CAVITIES

Plain chest radiography and computed tomography are the radiographic modalities most often used to image the chest. Ultrasound is a suboptimal modality for imaging the lung parenchyma because of poor sound transmission through the mostly air-filled lungs (237). Magnetic resonance imaging of the lung has been limited by motion artifact and relatively low spatial resolution (265), so this modality is not generally used to examine the lungs. Computed tomography is clearly more sensitive than plain chest radiography for the detection of pulmonary pathology, particularly in immunocompromised hosts. For example, one study of 61 patients at a single institution who had undergone bone marrow transplants for malignancies demonstrated that plain chest radiography was 58% sensitive in detecting pulmonary infection, compared to a sensitivity of 89% for computed tomography ($P < 0.0001$), with similar specificities for both modalities (328). Another study of 188 high-resolution computed tomography scans performed on 112 patients with febrile neutropenia and normal chest radiographs reported that 60% of the scans (112/188) had findings suggestive of pneumonia. However, these abnormal scan findings were not specific, as 46% of these 112 scans did not meet criteria for the diagnosis of pneumonia upon follow-up (150).

Characteristics of Cavities Used for Differential Diagnosis

The radiographic appearance of cavitory lesions can sometimes be useful to differentiate among a broad spectrum of etiologies but should be combined with clinical and laboratory data to obtain an accurate diagnosis. One traditional method used to classify cavitory lesions is wall thickness. Cavitory lesions associated with specific diseases are frequently described as being “thick walled” or “thin walled,” but exact definitions for these terms are often lacking. Of course, measured wall thickness will depend on the imaging technique used (plain radiography or computed tomography). Two studies examined the predictive utility of cavity wall thickness in solitary lung cavities as measured by plain radiography (399, 400). Those studies found that the measurement of the cavity wall thickness at its thickest section was most useful in predicting whether the cavity was of malignant versus nonmalignant etiology. Cavities with a maximum wall thickness of 4 mm or less were usually (30/32 [94% of the time]) caused by nonmalignant processes.

Cavities with a maximum wall thickness of 5 to 15 mm were mixed, with 33/55 (60%) being nonmalignant and 22/55 (40%) being malignant cavities. Cavities with a maximum wall thickness of >15 mm were usually (35/39 [90%]) malignant. In those two studies, the location of the lesions and the presence of an air-fluid level did not correlate well with malignant versus nonmalignant etiology. Another small study compared the characteristics, as observed on computed tomography scans of the lung, of cavities caused by lung cancer and nonmalignant cavities associated with intracavitary aspergilloma (290). Cavities associated with lung cancer in that study had significantly thicker walls than cavities associated with aspergillomas (mean wall thickness of 5.8 mm for lung cancers and 2.6 mm for aspergillomas; $P = 0.035$), but there was significant overlap in wall thickness between lung cancers and aspergillomas. Furthermore, cavity wall thickening observed using computed tomography may be an early sign of the development of an intracavitary mycetoma (325), so wall thickness is at best an imperfect tool for discriminating between malignant and nonmalignant etiologies of pulmonary cavities. The use of cavity wall thickness to discriminate among infectious etiologies of pulmonary cavities is even more problematic. While some infections, such as *Pneumocystis* pneumonia, coccidioidomycosis, and *Echinococcus*, have been classically associated with thin-walled cavities, the absence of comparative studies with systematic, objective measurements of cavity wall thickness among infectious etiologies severely limits the use of cavity wall thickness as a diagnostic tool in discriminating among infectious causes of cavities.

While wall thickness alone has at best questionable utility in discriminating between malignant and nonmalignant etiologies of a pulmonary cavity, other radiographic characteristics may provide additional clues to the nature of the underlying disease. The presence of a cavity on computed tomography of the lung essentially ruled out a viral infection in a small study ($n = 78$) of immunocompromised patients with lung infection, but the etiologies of cavities among these patients were about equally divided among bacterial, mycobacterial, and fungal infections (115). Another study of 131 adults in South Korea with cavities on plain radiography examined radiographic factors associated with specific disease etiologies (404). In that study, in which 50% of subjects had active or prior mycobacterial lung disease (primarily tuberculosis), the presence of the largest cavity in the upper lobes suggested a mycobacterial etiology, while lesions confined to only one lobe and the presence of multiple enlarged mediastinal lymph nodes were associated with another etiology (about half of which [31/65] were malignant). Nonradiographic factors such as age of >50 years and a history of malignancy were also associated with nonmycobacterial etiology. Of note, cavity wall thickness did not differ between subjects with mycobacterial cavities and those with nonmycobacterial cavities in that study.

NONINFECTIOUS DISEASES ASSOCIATED WITH LUNG CAVITIES

Malignancies

One of the most important distinctions in the differential diagnosis of cavitary lung lesions is the distinction between

malignant and nonmalignant etiologies. Primary lung cancer is a common disease, with 190,297 incident cases and 150,997 deaths reported in the United States in 2003 (370). Cavitation detected by plain radiography has been noted in 7 to 11% of primary lung cancers (58, 92, 247, 261), while cavitation detected by computed tomography has been reported for up to 22% of primary lung cancers; cavitation is more frequently found among cases of squamous cell carcinomas than other histological types (58, 247, 283). Furthermore, the presence of cavitation in a lung tumor has been associated with a worse prognosis (196). Other primary tumors in the lung, such as lymphoma and Kaposi's sarcoma, may also present with cavitary lesions, particularly among persons infected with human immunodeficiency virus (208, 235). In one series of human immunodeficiency virus-infected persons with primary pulmonary lymphoma, 5/12 subjects had cavitary lesions noted on computed tomography scans of the chest (305). Lymphomatoid granulomatosis, a rare malignant disorder associated with Epstein-Barr virus and clonal B-cell replication, frequently presents with pulmonary cavities and may be confused with lung abscess (240). Metastatic disease from other primary sites may also cavitate, but this occurs less frequently than in primary lung cancers: an estimated 4% of metastatic tumors have been noted to cavitate as detected by plain radiography (92). Interestingly, metastatic tumors of squamous cell origin are also more likely to cavitate than tumors of other origins, suggesting a common pathogenesis for cavitation among these tumors.

Complicating the diagnostic evaluation of cavitary lung lesions is the not-infrequent coexistence of pulmonary infection and malignancy. Multiple cases in which cavitary pulmonary lesions represent a combination of malignancy and an infectious pathogen have been reported. One prospective study based at a single center in Taiwan examined 22 patients with cavitary lung lesions, without evidence of postobstructive pneumonia, for whom ultrasound-guided transthoracic needle biopsy was performed (215). Nine pathogens were isolated from seven of the 22 patients, including *K. pneumoniae* (3 patients), *Haemophilus influenzae* (2 patients), *Bifidobacterium* (1 patient), *Enterococcus faecium* (1 patient), *M. tuberculosis* (1 patient), and *Shewanella putrefaciens* (1 patient). Additionally, multiple case reports described coexistent malignancy and infectious pathogens in cavitary lung lesions. In particular, primary lung cancer and tuberculosis are not infrequently encountered together, and either one can be responsible for cavitary lesions (190). The causal pathway for this association can go both ways: chronic inflammation and scarring caused by tuberculosis may contribute to the development of malignancy at the site, or immunosuppression associated with cancer and treatment may result in the reactivation of tuberculosis. Other mycobacterial or fungal pathogens can also coexist in malignant cavities; one report described concurrent *Aspergillus*, *Mycobacterium xenopi*, and lung cancer in a single patient (343).

Rheumatologic Diseases

Many autoimmune diseases can affect the lung, but cavitation is relatively uncommon in most of these diseases. The exception is Wegener's granulomatosis, an uncommon disorder in which cavitary lung disease is frequently encountered.

Wegener's granulomatosis is a systemic vasculitis that almost always involves the upper or lower respiratory tract. Pulmonary nodules and infiltrates are a frequent manifestation of Wegener's granulomatosis in the lung, and cavitation may accompany both of these manifestations. One study of 77 persons with Wegener's granulomatosis found that 26/53 (49%) persons with pulmonary nodules had cavitation (on plain radiograph or computed tomography) within one or more nodules and that 7/41 (17%) persons with infiltrates had cavitation within an area of infiltrate (subjects could have both nodules and infiltrates, so numbers do not equal 77) (77). Another study found cavitory nodules in 7/19 (37%) subjects with Wegener's granulomatosis detected by plain chest radiographs (3). The clinical picture was frequently complicated by infection in these subjects, as 3/19 (16%) subjects had subsequent bacterial superinfection of a lung cavity. Pulmonary cavities have been observed by computed tomography in 35 to 50% of patients with Wegener's granulomatosis involving the lung (203, 213, 236).

Sarcoidosis is a relatively common inflammatory disorder of unknown etiology that frequently affects the lungs (19). Plain chest radiographic findings are often nonspecific; conventional and high-resolution computed tomography are better modalities for showing characteristic features of pulmonary sarcoidosis (266). Hilar and mediastinal lymphadenopathy are usually present, with or without concomitant parenchymal abnormalities. Lung nodules are frequently observed and tend to be distributed along the bronchovascular bundles, interlobular septa, major fissures, and subpleural regions (266). Cavitation occasionally occurs within these nodules; for example, one study demonstrated cavitation in 3/44 (6.8%) patients with pulmonary sarcoidosis (29). Additional findings by computed tomography include fibrosis (honeycomb, linear, or associated with bronchial distortion), pleural thickening, and ground-glass opacities (1, 29).

Pulmonary cavities are less frequently encountered in other autoimmune diseases. Given that most patients with these diseases are treated with potent immunosuppressive agents, infectious etiologies for cavitory lesions should be aggressively investigated. However, cavitory lung lesions have been reported as being rare consequences of many autoimmune diseases. For example, patients with ankylosing spondylitis frequently (50 to 85%) have pulmonary abnormalities detectable by high-resolution computed tomography (45, 99, 330, 369), although a much smaller proportion have abnormal plain chest radiographs (1.3% in one large series) (319). Relatively common findings among patients with ankylosing spondylitis-associated lung abnormalities are apical fibrosis and bulla formation, both of which may appear radiographically as cavitation. Cavitation detected only by computed tomography in these patients is of uncertain clinical significance, but when cavities are visible by plain radiography, the etiology is commonly infection. For example, of 2,080 patients with ankylosing spondylitis in one series, 28 (1.3%) had lung abnormalities detected by plain radiography, most commonly apical fibrobullous lesions (319). Of these 28 patients, 7 had infectious etiologies for cavitory lesions: 5 had aspergillomas, and 2 had nontuberculous mycobacterial infections. Similarly, cavitory lesions in patients with systemic lupus erythematosus have also been reported, but most of these lesions represent infection. One

small series found six patients with cavitory lung lesions among a population of 798 patients with systemic lupus erythematosus seen at one center; four of the six had infectious etiologies for the cavities (two mixed bacterial infections with gram-positive and gram-negative organisms, one *Pseudomonas aeruginosa* infection, and one *Aspergillus fumigatus* infection), one cavity possibly represented pulmonary infarction, and only one patient had cavities that were likely attributable to lupus (386). Rheumatoid arthritis is also commonly associated with pulmonary abnormalities, but cavities due primarily to rheumatoid arthritis are rare. Lung cavities in patients with rheumatoid arthritis often represent infection or carcinoma, so aggressive diagnostic evaluation is warranted for new cavitory lesions in these patients (172). In rare cases, rheumatoid nodules may appear in the lung and cavitate, presumably due to ongoing vasculitis with ischemic necrosis (185, 408). Primary amyloidosis is another rare autoimmune cause of pulmonary cavities (354).

Miscellaneous Diseases Associated with Cavities

Various other noninfectious disease processes have been associated with lung cavities. Of these, the most common is pulmonary embolism. While pulmonary embolism is usually associated with nonspecific radiographic changes or even a normal chest radiograph (402), pulmonary infarction and necrosis may result in a cavitory lesion. Pulmonary embolism usually occurs when a clot forms in a lower extremity or the pelvis and subsequently breaks off and lodges in a pulmonary artery. However, pulmonary embolism may also be caused by tumor, fat (associated with trauma), air bubbles, septic emboli (see below), or injected foreign substances such as talc (145). Pulmonary infarction has been estimated to occur in 10 to 15% of cases of pulmonary embolism in older studies (217, 260); more recent studies using computed tomography noted infarction in up to 32% of patients with pulmonary embolism (148). In turn, cavitation has been observed on plain radiographs in 2.7 to 7% of patients with pulmonary infarction (67, 217) and in up to 32% of patients with pulmonary infarction detected by computed tomography (148). The lesions tend to be located in the lung periphery but may be located in any lobe, and there is nothing specific about the distribution or appearance of the cavities (391). Immunocompromised hosts are often at risk for pulmonary embolism due to underlying malignancy, surgical procedures, and immobility, so aseptic pulmonary embolism may be an underappreciated cause of lung cavities in these hosts (258). Cavities associated with venous thromboembolism may be observed 2 to 63 days after the embolic event and, in most cases, are initially aseptic (217, 391). However, superinfection of necrotic lung cavities is common, occurring in approximately one-half of cases (391); gram-negative rods are frequently implicated in these superinfections. Furthermore, superinfection with *Clostridium* species has been particularly associated with pulmonary embolism and usually causes a necrotizing, cavitory pneumonia that may further complicate the clinical picture (38).

A less common disorder associated with lung cavities is bronchiolitis obliterans organizing pneumonia, also called cryptogenic organizing pneumonia when there is no underlying etiology. This disorder, which is a pathological diagnosis, may

be triggered by drug or toxin exposure, autoimmune diseases, viral infections, or radiation injury but is most often idiopathic (272). Patients with bronchiolitis obliterans organizing pneumonia usually present with fever, cough, weight loss, and dyspnea over weeks to months, similar to many infectious diseases associated with lung cavities (76). The most common computed tomography appearance of this disorder is patchy consolidation, often accompanied by ground-glass opacities and nodules (214). Cavitation has been reported in 0 to 6% of cases, varying with the series and the imaging modality (76, 101, 214). Unfortunately, none of the clinical or radiographic manifestations of this disorder are specific, and diagnosis must be made by lung biopsy (101).

Another rare disease associated with lung cavities is pulmonary Langerhans' cell histiocytosis. The disease almost exclusively (over 90%) afflicts smokers, with a peak age of onset of between 20 and 40 years (357). Clinical presentation varies, but symptoms generally include months of dry cough, fever, night sweats, and weight loss (357). Thin-walled cystic cavities are the usual radiographic manifestation, observed in over 50% of patients by either plain chest radiography or computed tomography scans, but thicker-walled cavities are also commonly observed (30, 255). Diagnosis may be suggested by radiographic findings but must be definitively made by lung biopsy (357).

INFECTIONS ASSOCIATED WITH LUNG CAVITIES

Common Bacterial Infections

Infections caused by commonly encountered gram-positive or gram-negative bacteria may cause pulmonary cavities by one of two mechanisms. First, organisms may enter the respiratory cavity via the oropharynx/upper airway, bypass host defenses, and cause either a necrotizing pneumonia or lung abscess. Alternatively, organisms may enter the lung via the bloodstream, often in association with fibrin and platelets as septic pulmonary emboli. The radiographic appearance and microbiological etiologies of these two mechanisms are distinct and will be discussed separately.

Necrotizing pneumonias and lung abscesses. Lung cavities have not typically been associated with community-acquired pneumonia, but occasional cases of cavitary pneumonia due to *Streptococcus pneumoniae* or *Haemophilus influenzae* have been reported (312, 405). Of course, the prevalence of cavities among patients with community-acquired pneumonia depends on the imaging technique used; significantly more cavities are detected with computed tomography than with plain radiography. For example, among 17 children with severe pneumonia and cavitation detected by computed tomography, only 10 (59%) had cavities noted on plain radiographs (96). One series of 105 adults hospitalized with pneumococcal pneumonia reported that no patient had cavities detected by plain radiography (332); computed tomography was not routinely performed. On the other hand, a study of another series of 35 patients (43% with human immunodeficiency virus) with pneumococcal pneumonia reported that 7 (20%) had lung cavities detectable on computed tomography scans (345). Cavitation is more frequently reported among patients with concurrent *S. pneumoniae* pneumonia and bacteremia, which may reflect the

greater severity of disease among bacteremic patients (184). Similarly, a recent study of 75 children with empyema or parapneumonic effusion reported that 15 (20%) had associated cavitary lung disease, 13 of whom had evidence of *S. pneumoniae* infection (304). Because *S. pneumoniae* and *H. influenzae* are such common causes of pneumonia, these pathogens may cause a significant fraction of cavitary pneumonias, even though cavitation is relatively rare with these pathogens. This point is illustrated by a small case series of nine children hospitalized with cavitary pneumonia (as seen by computed tomography); the etiology was *S. pneumoniae* in three of nine patients and *S. pneumoniae* and *H. influenzae* in one patient (153).

Klebsiella pneumoniae is a common cause of severe, necrotizing pneumonia. While older literature described alcoholism and smoking as important risk factors for community-acquired *Klebsiella pneumoniae*, more recent studies demonstrate that a growing proportion of patients are immunocompromised and acquire infection in the hospital (43, 199). It has been a relatively common cause of community-acquired pneumonia (7.5% of all cases in North America) (152) and is particularly prevalent among patients with severe community-acquired pneumonia (22% of cases in one series) (286). *K. pneumoniae* pneumonia is frequently complicated by lung abscess, which generally appears as one or more cavities. In older series, 0 to 40% of patients developed lung abscess as noted on plain chest radiographs (43). A more recent series of 23 patients with *K. pneumoniae* pneumonia reported multiple small cavities ranging from 1 mm to 3 cm in diameter in 11 (48%) patients by computed tomography. Lung abscess due to *K. pneumoniae* can progress to destroy an entire section of a lung, a condition known as massive pulmonary gangrene. Pulmonary gangrene is a rare condition, but over one-half of cases are attributable to *K. pneumoniae* (296). Radiographically, this condition starts with lung consolidation, followed by the development of multiple small cavities that coalesce into one large cavity (84).

Staphylococcus aureus is an emerging cause of cavitary pneumonia (Fig. 1). In older series, *S. aureus* accounted for about 1% of community-acquired pneumonias (226). Plain chest radiographs frequently demonstrated cavitation in both adults and children. In one series of 26 adults and 8 children with community-acquired *S. aureus* pneumonia, 7 of the adults (27%) and 2 of the children (25%) had cavities detected by plain chest radiographs, while 4 adults (15%) and 3 children (38%) had pneumatoceles, defined as thin-walled cystic structures (227). More recently, community-acquired methicillin-resistant *S. aureus*, which usually possesses the Pantone-Valentine leukocidin virulence factor, has become an emerging cause of severe pneumonia. In contrast to classic staphylococcal pneumonia, which typically afflicted relatively debilitated patients in the nosocomial or health care-associated setting, community-acquired methicillin-resistant *S. aureus* pneumonia frequently affects immunocompetent hosts without significant prior exposure to the health care system. Pneumonia in these patients is frequently preceded by extrapulmonary staphylococcal infection, particularly skin infection. Community-acquired staphylococcal pneumonia is frequently severe. In one recent series of 50 patients, 78% required intubation and 42% had pulmonary hemorrhage, and overall in-hospital mortality

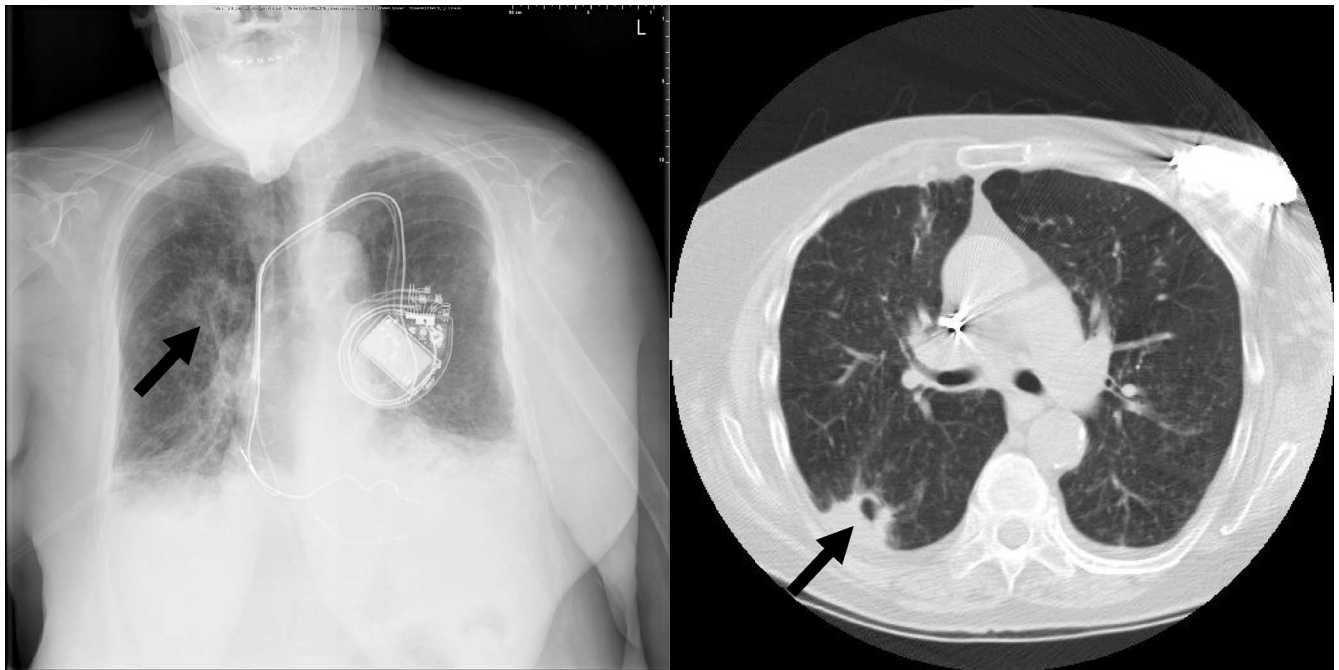


FIG. 1. Sequelae of severe *Staphylococcus aureus* pneumonia in a patient with multiple other comorbidities. The left panel illustrates the plain chest radiographic appearance, with multiple areas of fibrosis and a residual cavity in the medial right upper lobe. The right panel shows the same cavity using computed tomography.

was 56%. On plain radiographs, cavitation was noted in 12% of cases; multilobar consolidation (79%) and pleural effusions were more common (50%) (124).

Lung abscess is another relatively common bacterial cause of cavitary lung lesions. Most patients have one or more predisposing risk factors; in adults, alcoholism is usually the most frequently reported risk factor, but poor dentition, a prior history of aspiration, and underlying lung damage from other processes are all associated with the development of lung abscess (144). Lung abscess also occurs in children, most of whom have compromised immune systems or predisposing lung damage (49). The predominant organisms responsible for lung abscess in both adults and children are anaerobic and microaerophilic components of the oral flora, and lung abscesses are frequently polymicrobial (17, 49, 144). The most common organisms traditionally isolated from lung abscesses have been *Prevotella*, *Fusobacterium*, and streptococci (particularly the *Streptococcus milleri* group) (17, 144). A recent study from Taiwan, however, implicated *K. pneumoniae* as being the most common single cause of lung abscess, isolated from 28/90 (31%) patients with lung abscesses. Patients with *K. pneumoniae* lung abscess more often had diabetes or chronic lung disease than did other lung abscess patients, and the infection was usually monomicrobial (381).

Septic pulmonary emboli. Septic pulmonary emboli, although relatively rare, are important considerations in the differential diagnosis of cavitary lung lesions. Septic emboli typically appear as nodules located in the lung periphery, although wedge-shaped peripheral lesions and infiltrates are also seen (166). Cavitation is seen in 23 to 47% of cases using plain radiography and in up to 85% of cases using computed tomography (73, 158, 202). The presence of a “feeding vessel” sign, in

which a distinct vessel is seen leading to the center of a pulmonary nodule, suggests the diagnosis of septic embolus, but the specificity of this finding has been called into question (93). In older series, septic emboli were associated primarily with intravenous drug use and septic thrombophlebitis either in the pelvis or in the internal jugular vein (Lemierre syndrome) (228, 281). However, the etiologies of septic pulmonary embolism in more recent series are dominated by infected intravascular prosthetic material such as intravascular catheters, pacemaker wires, and right-sided prosthetic heart valves (73). Septic pulmonary emboli associated with intravenous drug use are caused predominantly by *S. aureus* (46, 281). Conversely, septic emboli associated with intravascular prosthetic material have been associated with a number of pathogens. For example, in a recent series at the Mayo Clinic, 7/14 cases of septic emboli were associated with intravascular prosthetic material (three central venous catheters, two prosthetic pulmonic valves, and two pacemakers) (73). The microbiological etiologies among patients with intravascular prosthetic material included three cases of *S. aureus*, two cases of coagulase-negative staphylococci, one case of *S. pneumoniae*, and one polymicrobial infection (coagulase-negative staphylococcus, *Corynebacterium*, and *Klebsiella oxytoca*). Septic thrombophlebitis of the internal jugular vein may also be catheter associated but has classically been associated with oropharyngeal infection and is termed Lemierre syndrome. Lemierre syndrome generally afflicts young persons in their late teens and early twenties but may also affect children and older persons (57, 73, 127). Most affected patients are immunocompetent and previously healthy. The majority of cases of Lemierre syndrome are associated with *Fusobacterium necrophorum* (71.6% in one large series) (57), but many are mixed infections composed of anaerobes

normally present in the oral cavity. Almost all patients with Lemierre syndrome have pulmonary manifestations, including infiltrates and pleural effusions; cavities were seen in 31% of patients in one series (57). Apart from Lemierre syndrome, community-acquired methicillin-resistant *S. aureus* is increasingly associated with septic pulmonary emboli, particularly among children with bone and joint infections (130). Among profoundly immunocompromised persons, septic emboli due to nontyphoid *Salmonella* strains have been described. Persistent and recurrent *Salmonella* bacteremias, often with extraintestinal manifestations, are not rare among persons with advanced human immunodeficiency virus (131) and have been reported for other immunosuppressed hosts as well (5, 48). Pulmonary lesions have been reported in up to 35% of patients with advanced human immunodeficiency virus and *Salmonella* bacteremia (usually *S. enterica* serovar Enteritidis or *S. enterica* serovar Typhimurium), and in one report, 70% of patients with pulmonary manifestations of *Salmonella* had cavities detected by plain chest radiographs (44).

Uncommon Bacterial Infections

Actinomycosis. *Actinomyces* species are gram-positive rods that normally colonize the human digestive tract. Approximately 50% of disease caused by actinomycosis is cervicofacial, 20% involves the abdomen or pelvis, and 15% is pulmonary (70, 225). *Actinomyces israelii* is the most commonly isolated pathogen in all of these disease manifestations, but other species (*Actinomyces naeslundii*, *A. odontolyticus*, *A. viscosus*, *A. meyeri*, and *A. gerencseriae*) are also frequently implicated in disease (225). *A. meyeri*, in particular, may have a greater propensity to cause pulmonary disease as well as to disseminate (11). Alcoholism and poor oral hygiene have been associated with *Actinomyces* infection (11, 22). Pulmonary actinomycosis may occasionally result from the contiguous spread of infection from the neck but is usually caused by aspiration of saliva or other material containing *Actinomyces* (70). This aspiration results in pneumonitis followed by local necrosis, fibrosis, and cavitation (33). Not surprisingly, many *Actinomyces* infections are polymicrobial and include other components of the oral flora such as *Eikenella corrodens*, streptococci, *Actinobacillus*, or *Fusobacterium* (155). Pulmonary actinomycosis generally progresses slowly with nonspecific symptoms including nonproductive cough, low-grade fever, and malaise (341). The insidious nature of the disease, its proclivity to appear as a mass lesion on chest radiography, and the occasional presence of concurrent extrapulmonary disease make it easily confused with malignancy (68, 356). Cavitory lesions are common but may be visible only by computed tomography. For example, two recent series demonstrated cavitory lesions on plain radiographs in 0 and 13% of cases, respectively, but cavities were detected by computed tomography in 62% and 75% of cases (55, 206). Associated pleural thickening or effusion is common, and as the infection erodes through tissue planes, empyema necessitatis with drainage through the chest wall or into other spaces may complicate pulmonary actinomycosis (33, 113).

Nocardia. *Nocardia* species are gram-positive, weakly acid-fast organisms naturally found in the soil. Infection is presumably acquired via either inhalation or direct inoculation due to trauma. Over 50 species of *Nocardia* have been identified, with

about 16 implicated in human infection. Traditionally, most isolates causing human disease were identified as being *Nocardia asteroides*, but molecular taxonomy has demonstrated that many of these isolates were misidentified, so the relationships between species and disease manifestations are changing rapidly (35). Pulmonary disease is the most common presentation of *Nocardia* infection and accounts for over one-half of reported cases in most series (105, 267, 301). The most common risk factor for pulmonary nocardiosis is underlying lung disease such as asthma, bronchiectasis, or chronic obstructive pulmonary disease (105, 159, 301). Persons with systemic immunodeficiencies associated with cancer chemotherapy, human immunodeficiency virus, organ transplant, and long-term corticosteroid use are also at risk for pulmonary *Nocardia* infection, but approximately 15% of patients will have no underlying disorder (159, 234). Disease onset is usually subacute, and symptoms including fever, cough, and dyspnea are usually present for several days to several weeks before diagnosis (244). The manifestations of *Nocardia* infection detected by plain chest radiography include multifocal consolidation, irregular masses, single or multiple nodules, and pleural effusions (106). Cavitation results from tissue necrosis and abscess formation and may be observed on plain radiographs in 38 to 62% of cases (106, 273). Computed tomography frequently reveals multiple nodules and pleural involvement, with cavitation in up to 80% of cases (407). Cavitation may be more frequently observed among persons with advanced human immunodeficiency virus than among other hosts (36). *Nocardia* infection may be associated with mortality rates as high as 30 to 40%, particularly among hosts with severe immune compromise (234, 244).

Melioidosis. Melioidosis, the term given to disease caused by the gram-negative rod *Burkholderia pseudomallei*, can affect any organ system but most commonly affects the lung (165). It is endemic in tropical areas, especially Southeast Asia and Northern Australia, although disease in rural areas in South and Central America is probably underrecognized (164). Infection usually occurs through contact with or ingestion or inhalation of contaminated soil or water. Independent risk factors for melioidosis include occupational exposure (such as from rice farming), diabetes, chronic renal disease, and thalassemia (353). Pulmonary disease can present in an acute or chronic form and either be localized or part of disseminated infection (165). Furthermore, infection can be latent and reactivate many years after exposure, such as is observed in Vietnam war veterans who develop disease many years after returning to the United States (198). Acute pulmonary disease presents as high fever, chills, coughing, chest pain, and dyspnea. Plain radiographs most commonly demonstrate alveolar or nodular infiltrates, and cavitation is relatively common (26% in one series of 183 patients in Northern Thailand) (91). Conversely, subacute or chronic pulmonary disease usually presents radiographically with nodular and/or alveolar infiltrates accompanied by cavities; 50% of nonbacteremic patients with subacute pulmonary disease and 68% of nonbacteremic patients with chronic pulmonary disease had cavities detected on plain chest radiographs in the same Thai series. Patients with subacute/chronic disease and concurrent bacteremia tend to have a lower prevalence of cavities (0 to 29%) than patients with subacute/chronic melioidosis without bacteremia (60%) (91, 264).

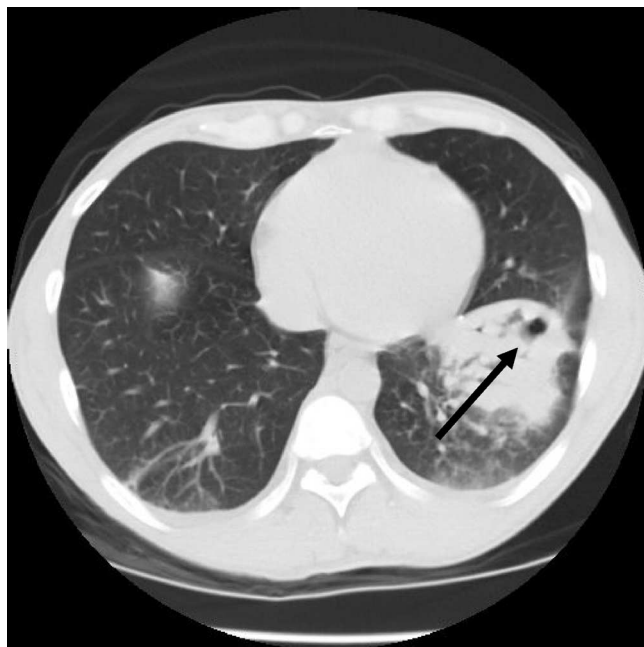


FIG. 2. Left lower lobe cavitary pneumonia due to *Rhodococcus equi* with concurrent bacteremia in a patient with advanced human immunodeficiency virus.

Rhodococcus. *Rhodococcus equi* is a gram-positive coccobacillus commonly isolated from soil, especially farm soil that has been contaminated with horse manure (355). The organism is a common cause of pneumonia in young horses and is shed in the feces of mares (138). Exposure to livestock is a recognized risk factor for infection, although many patients will not have this exposure (181, 205). Infection occurs primarily through inhalation (274), although infection may also be acquired by ingestion or traumatic inoculation (376). *R. equi* is increasingly being recognized as a human pathogen, particularly in those with advanced human immunodeficiency virus infection (CD4⁺ T-lymphocyte count of <200 cells/mm³) (133, 385), hematologic malignancies (223), and use of chronic corticosteroids and other immunosuppressive agents (120) and in recipients of solid-organ and stem cell transplants (79, 205, 268, 297). Depending on the series, up to 10 to 15% of cases occur in immunocompetent individuals (118, 181, 376).

Pulmonary disease is the most common manifestation of *R. equi* in immunocompromised patients, occurring in approximately 80% of cases (268, 270, 364, 376) (Fig. 2). Immunocompetent patients are more likely to have extrapulmonary disease, with approximately 40% of reported cases of *R. equi* disease in immunocompetent hosts affecting the lungs (181). Pulmonary *R. equi* generally presents with insidious onset of fever, dyspnea, cough (frequently nonproductive), and pleuritic chest pain (181, 270). Chest radiographs are usually abnormal, most frequently demonstrating dense infiltrates with or without upper lobe cavitation (270, 364). Cavitation detected by plain chest radiography has been observed in 63% of immunocompetent patients with pulmonary *R. equi* infection (181) and in 41% to 77% of human immunodeficiency virus-infected patients (94, 270, 364). One small ($n = 5$) study demonstrated cavitation in all patients using computed tomography

(233), while another study ($n = 9$) demonstrated cavitation in 44% of patients using plain radiography and 67% of patients using computed tomography (390). Nodular infiltrates, pleural effusion, and mediastinal lymphadenopathy are other common radiographic features (233, 270, 390). A majority of immunocompromised patients with pulmonary disease will have concurrent bacteremia, so routine blood cultures are high yield in this population (94, 364).

Mycobacterial Infections

Mycobacterium tuberculosis. *Mycobacterium tuberculosis* is classically associated with cavitary pulmonary disease (Fig. 3). Although tuberculosis case rates have declined in many developed countries, the human immunodeficiency virus epidemic has led to a tremendous increase in tuberculosis cases in the developing world, particularly in sub-Saharan Africa (75). In addition to human immunodeficiency virus infection, other risk factors for tuberculosis include exposure-related factors such as birth in a country where tuberculosis is endemic (294) and immunologic deficits that increase the risk of progression from latent to active tuberculosis, such as diabetes (188), hematologic and head and neck malignancies (175), organ transplantation, corticosteroid use, and tumor necrosis factor antagonist use (8, 180). Pulmonary tuberculosis generally presents subacutely, with weeks to months of productive cough, fever, night sweats, weight loss, and, occasionally, hemoptysis. The chest radiograph typically reveals pulmonary infiltrates in the apical and posterior segments of the upper lobe or the superior segment of the lower lobe, often associated with cavitation (248, 371). The prevalence of cavities on plain radiographs varies widely by series, but most series report cavitation in 30 to 50% of patients. Multiple cavities are often present and frequently occur in areas of consolidation (142, 238, 401). Cavities can vary widely in size and have been reported to have both thick and thin walls (142, 371, 393). The presence of cavitation is associated with a greater degree of infectiousness, likely due to higher organism burden (315). Supporting the association between cavitation and organism burden, cavitary disease is independently associated with increased time for acid-fast smears and cultures to become negative in patients receiving tuberculosis therapy as well as an increased risk of relapse after treatment completion (21). Similar to other cavitary lung diseases, computed tomography is more sensitive than plain radiography for the detection of tuberculous cavities (162, 238). Due in part to this increased sensitivity, the presence of cavitation detected by computed tomography scans does not necessarily carry the same clinical, prognostic, and public health impact as the presence of cavitation detected by plain radiography.

Host factors play a significant role in the prevalence of cavitation. Cavitation is highly prevalent among diabetic patients with tuberculosis (382), whereas cavities have been less frequently observed in the elderly (298, 382) and persons with advanced human immunodeficiency virus infection (222).

Nontuberculous mycobacteria. Over 120 species of nontuberculous mycobacteria, also known as mycobacteria other than tuberculosis or potentially pathogenic environmental mycobacteria, have been described (365). Unlike organisms belonging to the *M. tuberculosis* complex, nontuberculous myco-

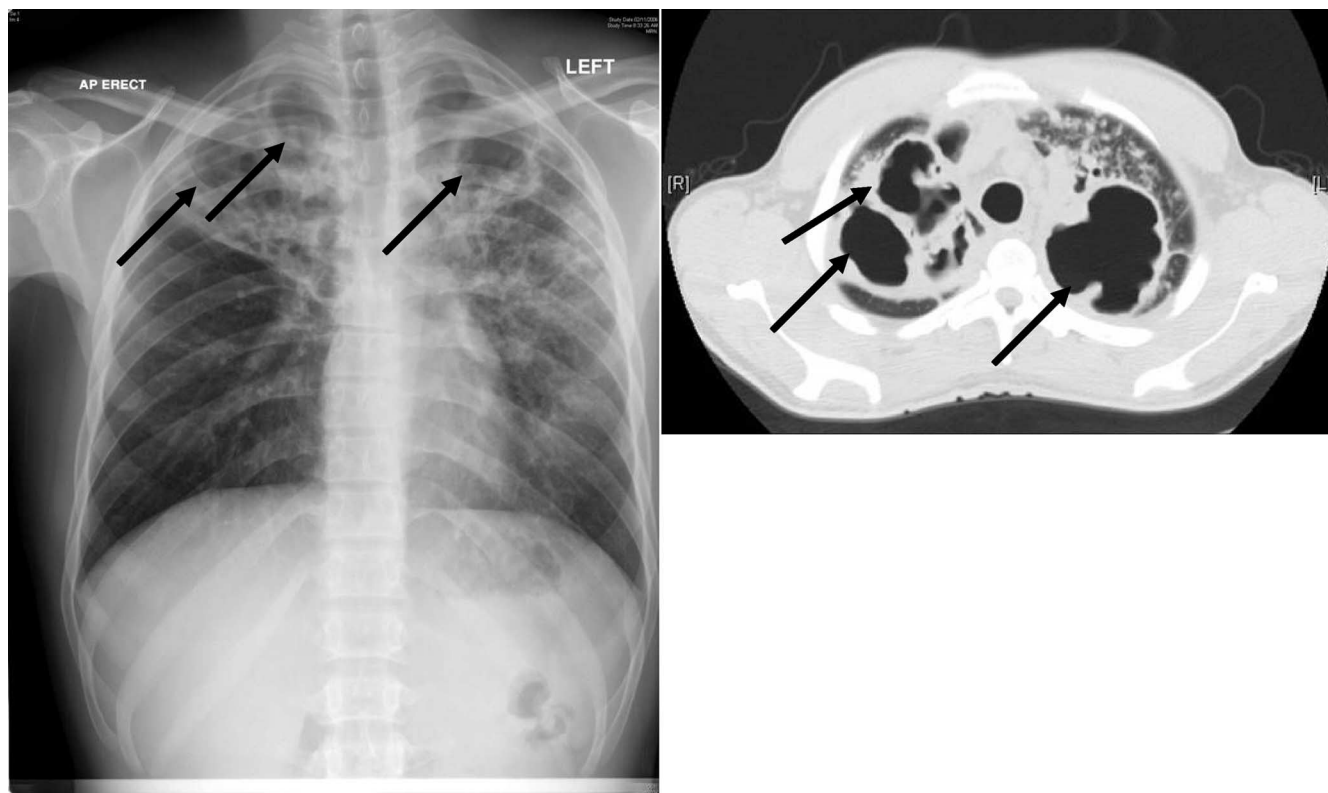


FIG. 3. Extensive cavitary lung disease due to *Mycobacterium tuberculosis* visualized by plain chest radiography (left) and computed tomography (right). Note the typical upper lobe predominance and extensive fibronodular infiltrates.

bacteria are acquired from environmental exposure and are not transmissible from person to person (110). Nontuberculous mycobacteria are present in soil, water, and dust, so pulmonary infection occurs presumably via inhalation of infectious aerosols (191, 291). Pulmonary disease due to nontuberculous mycobacteria frequently presents with nonspecific symptoms such as chronic cough, fatigue, and weight loss. The syndromes caused by pulmonary infection by nontuberculous mycobacteria overlap significantly with each other and with tuberculosis, making the microbiological data crucial for obtaining the correct diagnosis. Furthermore, the isolation of any nontuberculous mycobacterium from a respiratory specimen may represent laboratory contamination, colonization, or true disease, so standardized diagnostic criteria are available to assist clinicians (136). In the next section, we will discuss some of the nontuberculous mycobacteria most commonly associated with pulmonary disease, recognizing that our understanding of species designations and their associations with particular disease syndromes is evolving.

(i) ***Mycobacterium avium* complex.** Organisms belonging to the *Mycobacterium avium* complex are the nontuberculous mycobacteria most frequently implicated in pulmonary disease in the United States (136). The *M. avium* complex includes two major species, *M. avium* and *M. intracellulare*, as well as a third group of organisms, many of which do not belong to named species (366). Early reports described a disease very similar to tuberculosis, manifesting as apical fibrocavitary disease in middle-aged men with a significant smoking history and underlying

lung disease (321) (Fig. 4). Alcoholism and prior tuberculosis disease are also putative risk factors. Most patients complain of chronic cough; constitutional symptoms are not usually present until late in the disease. As the diagnosis was often made, in part, on the basis of cavitation, plain radiographs showed cavities in up to 88% of cases (59). In more recent years, the spectrum of lung disease caused by the *M. avium* complex has expanded. Probably the most common manifestation of *M. avium* complex pulmonary disease is the nodular/bronchiectatic form. This entity usually afflicts thin women over 50 years of age who have otherwise normal immune systems and no previous diagnosis of lung disease (302). Gastroesophageal reflux seems to be a significant risk factor, and aspiration may play a significant role in the pathogenesis of the disease (195, 360). Cavitation is rarely visible on plain chest radiographs, but computed tomography scans reveal cavities in up to 62% of cases (224, 395). Other typical radiographic features detected by computed tomography include nodules with associated bronchiectasis, particularly in the lingula and/or right middle lobe (64, 154, 224). Obtaining a microbiological diagnosis from sputum specimens is often difficult in patients with nodular/bronchiectatic *M. avium* complex pulmonary disease; in one series, 45% of patients required bronchoscopy or lung biopsy to obtain a diagnosis (157). Computed tomography scans may be helpful to refine the diagnostic approach for patients with suspected *M. avium* complex pulmonary disease, as cavitation detected by computed tomography has been positively correlated with the likelihood of obtaining a positive sputum culture

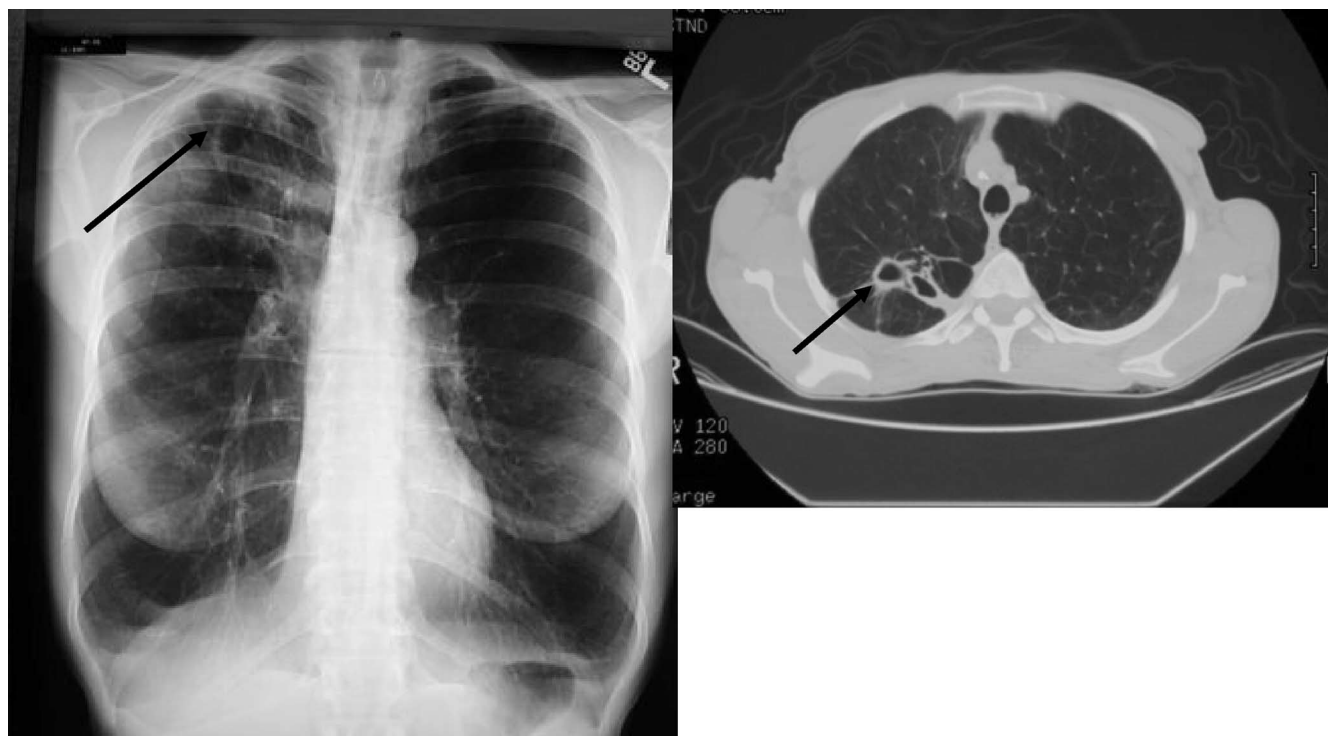


FIG. 4. *Mycobacterium avium* complex of the fibrocavitary type in a 52-year-old woman with chronic obstructive pulmonary disease visualized by plain radiography (left) and computed tomography (right).

(224). The *M. avium* complex can also cause solitary pulmonary nodules and hypersensitivity pneumonitis, but these entities are not associated with cavitation (147, 186, 194).

(ii) *Mycobacterium kansasii*. *Mycobacterium kansasii* is often considered to be the most virulent of the nontuberculous mycobacteria because the isolation of this organism from clinical specimens usually indicates clinically significant disease (24). In the United States, *M. kansasii* is endemic to the south and central states, with Texas, Louisiana, Florida, Illinois, Kansas, and Nebraska having the highest incidences of disease (135). However, sporadic cases have been reported across the world, with high rates of *M. kansasii* disease being reported from parts of the United Kingdom and in South African gold miners (74, 406). Predisposing factors include smoking-related lung disease, alcoholism, prior tuberculosis, and human immunodeficiency virus infection (74, 230). Symptoms are often indistinguishable from those of tuberculosis and include productive cough, shortness of breath, and occasional hemoptysis (103). Cavitation is almost always visible on plain radiographs in older published series (87 to 96% had cavities) and may be single or multiple, predominantly involving the upper lobes (60, 230). Classically, *M. kansasii* pulmonary disease has been associated with thin-walled cavities (411) (Fig. 5), but thin-walled cavities are actually present in a minority of patients with *M. kansasii* pulmonary disease (60). The clinical and radiographic picture is essentially indistinguishable from that of tuberculosis, which makes initial diagnosis difficult, particularly in regions where tuberculosis is endemic (74). More recent studies have demonstrated that *M. kansasii* can also cause radiographic changes similar to the nodular/bronchiectatic pat-

tern associated with the *M. avium* complex. A recent small study of nine patients with *M. kansasii* described primarily nodules, bronchiectasis, and tree-in-bud opacities detected by computed tomography, with cavitation in only four (44%) cases (154). *M. kansasii* is a significant cause of pulmonary disease among persons with advanced human immunodeficiency virus infection (24). While human immunodeficiency virus-infected patients with pulmonary *M. kansasii* infection have symptoms similar to those of their immunocompetent counterparts, alveolar infiltrates are the most common manifestation detected by plain chest radiography, especially in those with very low CD4⁺ T-lymphocyte counts. In one study, cavitation was seen in only 3/19 (19%) patients with *M. kansasii* pulmonary disease and advanced human immunodeficiency virus infection (mean CD4 count of 24 cells/mm³) (112). Some patients with advanced human immunodeficiency virus and apparent *M. kansasii* pulmonary disease will even have normal chest radiographs (318).

(iii) *Mycobacterium malmoense*. *Mycobacterium malmoense* disease is increasingly being reported in England, Wales, and Northern Europe, where it rivals the *M. avium* complex as a cause of chronic pulmonary infection (32, 149). Patients are commonly Caucasian and male and have preexisting lung damage from smoking, prior tuberculosis, or pneumoconiosis (102, 149). Clinical presentation includes productive cough, hemoptysis, and weight loss. Cavitory lesions are prominent radiographic findings in *M. malmoense* pulmonary disease, noted on plain chest radiographs in 38 to 69% of cases (32, 102, 149). While one study demonstrated some statistically significant radiographic differences between *M. malmoense* pulmonary

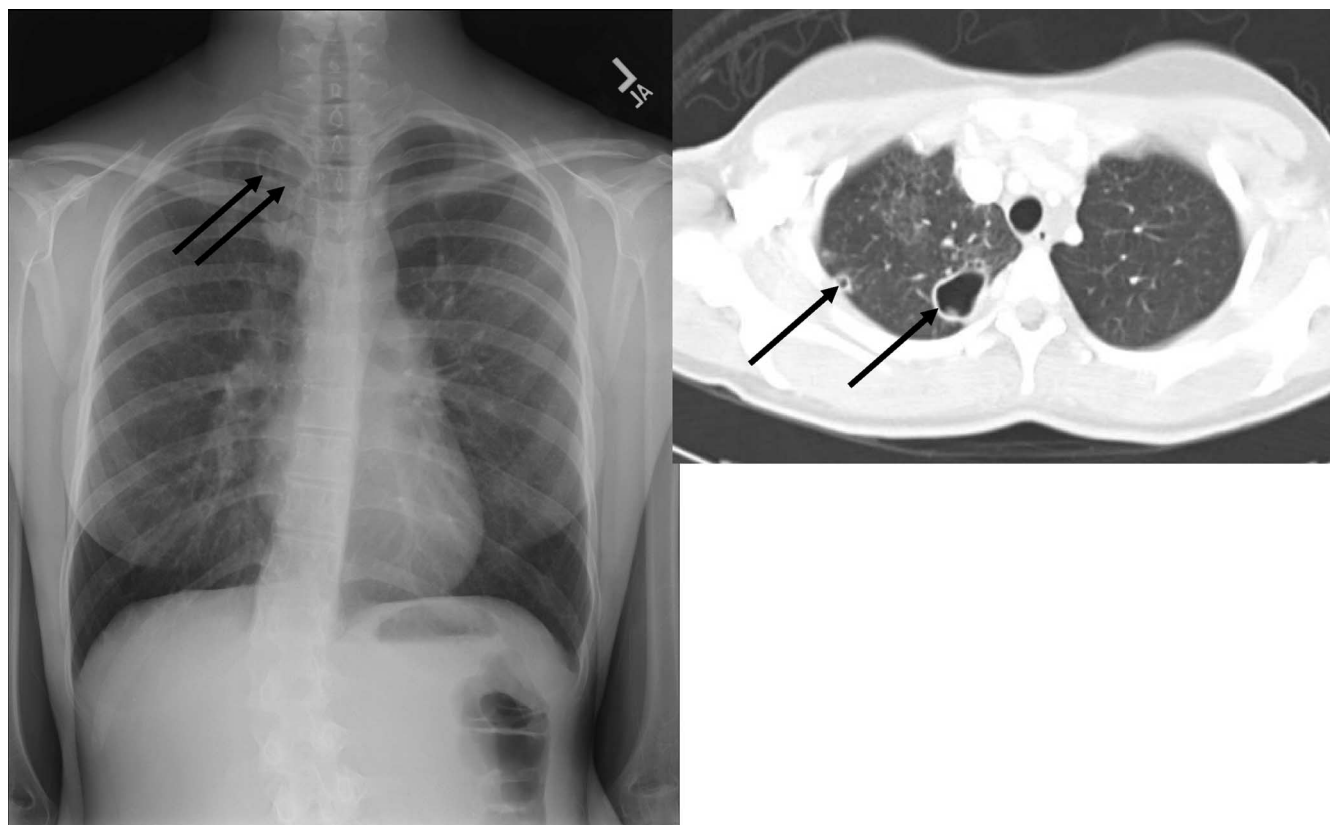


FIG. 5. *Mycobacterium kansasii* pulmonary disease presenting as 8 months of hemoptysis without any systemic symptoms in a 16-year-old girl. The thin-walled cavities (in the right apex) are relatively subtle on plain chest radiography (left) but are readily apparent by computed tomography, as is the accompanying bronchiectasis (right).

disease and tuberculosis, these differences were not large enough to be clinically useful, so a microbiological diagnosis is essential (102).

(iv) ***Mycobacterium xenopi***. *Mycobacterium xenopi* is an emerging pulmonary pathogen in Canada, the northeastern United States, the United Kingdom, and Europe (95, 231, 338, 359). In particular, *M. xenopi* is increasingly being isolated from respiratory specimens obtained from persons with human immunodeficiency virus infection, but the clinical significance of these isolates is questionable (95, 183, 231). Cavities are commonly (up to 81%) observed on plain radiography in patients without human immunodeficiency virus infection (169) but are rare among persons with *M. xenopi* pulmonary disease and human immunodeficiency virus coinfection. For example, in one series of 35 patients with advanced human immunodeficiency virus infection and nontuberculous mycobacterial infection (23 of whom had *M. xenopi*), only 1 patient (3%) had a cavity detected by plain chest radiography (100). As with *M. kansasii*, more modern series are recognizing that nodules and bronchiectasis are significant radiographic components of *M. xenopi* disease. In a recent small ($n = 9$) study of patients with *M. xenopi* pulmonary disease who had computed tomography performed, all nine had bronchiectasis, eight of nine (89%) had nodules, and five of nine (56%) had cavitation.

(v) **Rapidly growing mycobacteria**. Rapidly growing mycobacteria are increasingly being recognized as a cause of chronic lung disease. Among the rapidly growing mycobacteria, *Mycobacterium abscessus* is the predominant pathogen, accounting

for 82% of infections in one large series of patients with pulmonary disease due to rapidly growing mycobacteria ($n = 154$); other pathogens in this series included *M. fortuitum* and *M. chelonae* (137). Most affected patients are nonsmoking Caucasian women that are middle-aged or older. Gastroesophageal reflux and/or achalasia have been implicated as being risk factors for pulmonary disease with these organisms (137, 141, 195). Due to its prevalence, the radiographic findings of *M. abscessus* have been best described. Cavitory lesions, often visible only by computed tomography, have been reported in 16 to 42% of patients (137, 146). Other findings commonly include the tree-in-bud pattern (branching nodular opacities), bronchiectasis, well-defined nodules, consolidation, and cavities. While cavitation is less common among patients with *M. abscessus* than among those with *M. avium* pulmonary disease, the radiographic findings overlap and are not clinically useful to identify the causative organism (64).

Fungal Infections

Aspergillosis. *Aspergillus* species are environmental molds that cause a wide range of pulmonary disease in humans. Pulmonary disease is most commonly caused by *Aspergillus fumigatus*, although it can be caused by other species such as *A. flavus*, *A. niger*, and *A. terreus*, and can manifest as one of four distinct clinical entities, ordered by increasing pathogenicity and tissue invasion: (i) allergic bronchopulmonary aspergillo-

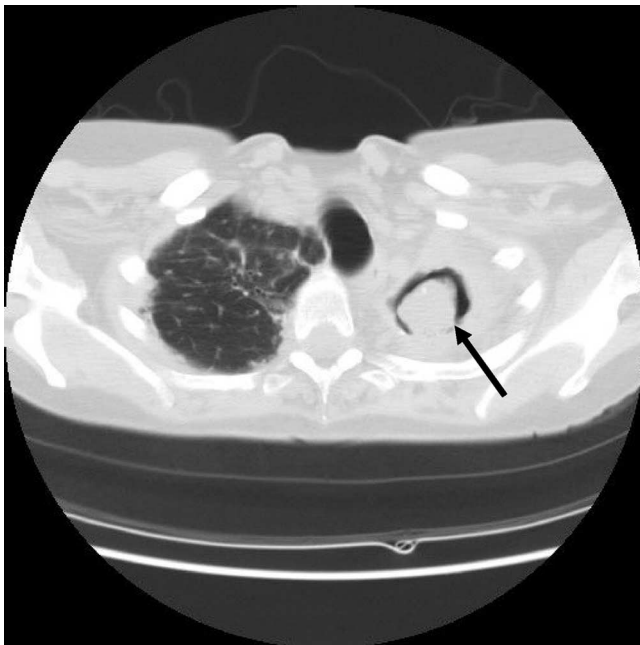


FIG. 6. Aspergilloma (round mass in the left upper lobe) visualized by computed tomography in a young man. The etiology of the underlying cavity was unknown in this case.

sis, which afflicts patients with long-standing asthma; (ii) aspergilloma, which afflicts primarily patients with preexisting lung cavities; (iii) chronic necrotizing aspergillosis or semi-invasive aspergillosis, which afflicts patients with a history of chronic lung disease; and (iv) invasive aspergillosis, which afflicts immunocompromised and critically ill hosts (342). Allergic bronchopulmonary aspergillosis is not generally associated with lung cavitation and will not be discussed further, but the other three manifestations of *Aspergillus* are all associated with pulmonary cavities.

An aspergilloma, also referred to as a mycetoma or fungus ball, represents growth of aspergillus (usually *A. fumigatus*) (299) within a preexisting lung cavity (Fig. 6). Classically, the most common cause of the cavity was pulmonary tuberculosis, and one older study reported radiographic evidence of aspergilloma formation in 11% of 544 patients with tuberculous pulmonary cavities (309). In areas where tuberculosis is endemic, tuberculosis is still the most common condition predisposing subjects to aspergilloma formation (6). However, any illness that causes a chronic, nonresolving pulmonary cavity produces an environment conducive to aspergilloma formation, and aspergillomas have been reported in association with most of the disease entities discussed in the present review. Radiographically, an aspergilloma appears as a rounded opacity within a previously existing cavity; computed tomography can more accurately delineate the mass and surrounding air crescent than plain radiography (6). Differentiating aspergilloma from malignancy is a significant issue, as there is considerable overlap in the appearances of the two conditions. Enhancement of the mass on computed tomography suggests malignancy, while adjacent bronchiectasis and a dependent location are more typical of aspergilloma (290). Other aspergilloma manifestations include thickening of the cavity wall,

a new air-fluid level within the cavity, or complete opacification of a previously air-filled cavity (12). Patients with aspergilloma are frequently asymptomatic, but the most common symptomatic presentation is hemoptysis (307, 309). Aspergillomas may grow or shrink over time, and a small percentage (5 to 10%) may spontaneously resolve (309).

Chronic necrotizing or semi-invasive aspergillosis generally occurs in middle-aged or elderly individuals with chronic lung disease or mildly immunosuppressive conditions such as alcoholism or diabetes. Most patients experience progressive constitutional symptoms over several months, including weight loss, malaise, and fatigue, and a chronic productive cough. Hemoptysis or only constitutional symptoms are also common (90). Chronic necrotizing aspergillosis differs from a simple aspergilloma in that a preexisting cavity need not be present but can be formed by the *Aspergillus* infection itself (123). Almost all patients have cavities observable on plain radiographs, predominantly in the upper lobes, although a minority may have only extensive fibrotic changes (90). Computed tomography may demonstrate consolidation or a mass in early disease, often accompanied by adjacent pleural thickening and distortion of lung architecture (220). Over months to years, these cavities expand and paracavitary infiltrates occur, with a progressive loss of functional lung (89).

Invasive pulmonary aspergillosis afflicts primarily severely immunocompromised patients, especially those with hematological malignancies, bone marrow transplant recipients, and those with long-term immunosuppressive or corticosteroid use (252, 342). Persons who have received allogeneic bone marrow transplants have the highest rates of invasive aspergillosis. Among recipients of solid-organ transplants, lung transplant recipients have the highest risk of invasive aspergillosis (140, 257). However, invasive aspergillosis among critically ill persons without malignancy or other immune compromise is becoming an increasingly recognized entity (243). Invasive aspergillosis has also been reported among persons with advanced human immunodeficiency virus, usually in association with neutropenia and corticosteroid treatment (216, 275). Symptoms include fever, dyspnea, nonproductive cough, and chest pain; many patients with prolonged neutropenia will present with persistent fever despite broad-spectrum antibacterial therapy (342). Early in disease, plain radiographs usually demonstrate consolidation or nodules with no evidence of cavitation. Computed tomography scanning is more useful for early diagnosis than plain radiography (Fig. 7). Specifically, the presence of a “halo sign,” defined as a nodule surrounded by a zone of ground-glass attenuation, is reasonably sensitive (70 to 80%) and specific (60 to 98%) for invasive aspergillosis in high-risk patients (26, 156, 292, 308). Cavitation generally occurs later in the course of the disease (1 to 2 weeks after the appearance of the halo sign) and is often noted during recovery from neutropenia in previously neutropenic patients (83, 122, 201). The onset of cavitation is heralded by the so-called “air crescent sign,” defined as crescents of air surrounding nodular lesions; further necrosis due to fungal angioinvasion and resultant ischemia results in progressive cavity formation in up to 63% of patients (4, 26, 156, 292).

Zygomycosis. Zygomycosis, also known as mucormycosis, refers to infection caused by molds belonging to the class Zygomycetes, with most clinically significant disease attrib-

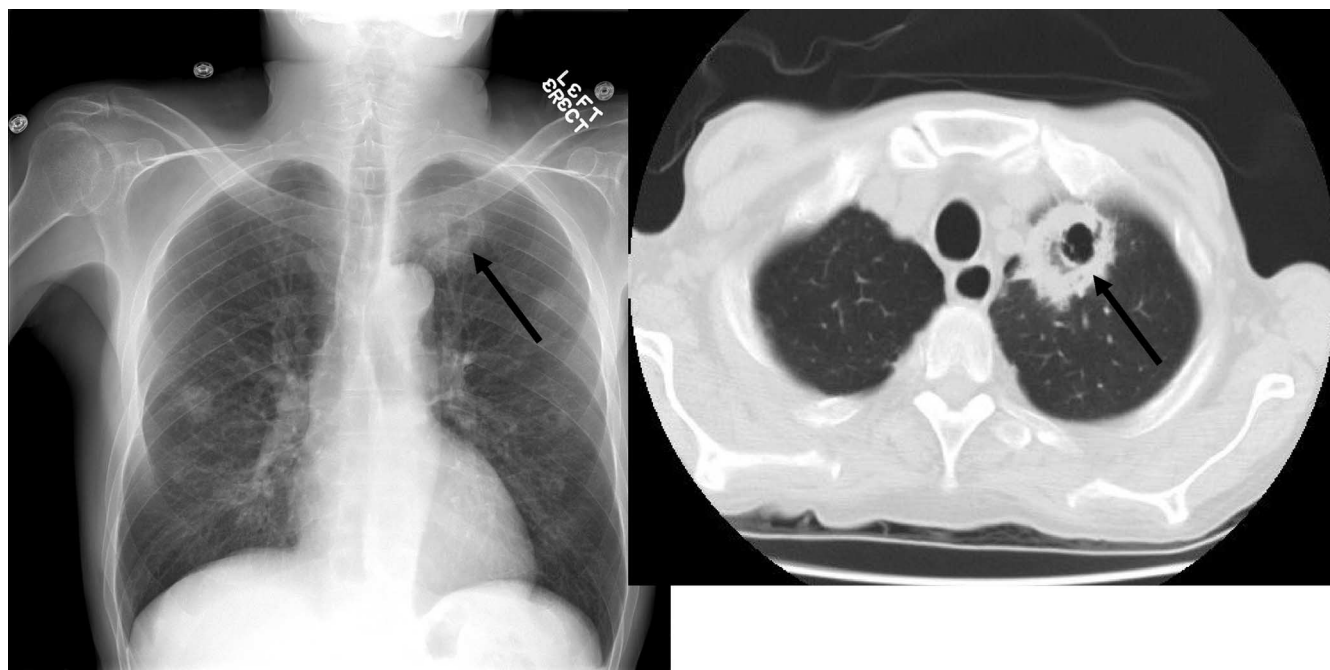


FIG. 7. Invasive aspergillosis in a 52-year-old man with systemic lupus erythematosus who had been on chronic high-dose corticosteroids and azathioprine. The plain chest radiograph (left) is suggestive of septic pulmonary emboli, with multiple large nodules bilaterally, at least two of which contain central cavities. The right panel demonstrates one of these thick-walled cavities as seen by computed tomography. This patient also had *Aspergillus* in the brain, which is a common site of metastatic spread in immunocompromised hosts.

uted, in descending order of frequency, to the genera *Rhizopus*, *Mucor*, *Cunninghamella*, *Apophysomyces*, and *Absidia* (314). These saprophytic fungi are found in soil and decaying organic matter, and infection is presumed to occur by inhalation (104). Zygomycetes are opportunistic pathogens that cause disease primarily in immunocompromised hosts, particularly persons with hematologic malignancies and poorly controlled diabetics. Pulmonary disease is the most common manifestation of zygomycosis among patients with underlying malignancy, while diabetics and patients with other risk factors more commonly have extrapulmonary disease (314). Patients commonly present with acute onset of cough and fever, with hemoptysis occurring less frequently (211). Pulmonary infiltrates are usually detected by plain chest radiography, with cavitation noted in 26 to 40% of cases (211, 239). Similar to invasive pulmonary aspergillosis, computed tomography frequently demonstrates multiple nodules with a halo sign, followed by an air crescent sign; mediastinal lymphadenopathy and pleural effusions are also commonly observed (167, 239). The overlaps in host characteristics and clinical manifestations between zygomycosis and invasive pulmonary aspergillosis cause considerable difficulty in distinguishing the two diseases; this distinction is important, as management differs for the two conditions. In one retrospective study of cancer patients, prior receipt of voriconazole prophylaxis, the presence of sinus involvement, greater than 10 pulmonary nodules on computed tomography, and the presence of a pleural effusion were strongly and independently associated with the diagnosis of pulmonary zygomycosis (compared to invasive pulmonary aspergillosis), but these data have not been prospectively validated (47).

Histoplasmosis. The dimorphic fungus *Histoplasma capsulatum* is one of the more common endemic mycoses, as it is found in soil worldwide. Disease due to *H. capsulatum* is highly endemic in the Midwestern United States, but low-level endemic disease has also been reported in Mexico, Central America, and South America as well as in parts of Southeast Asia (62, 121, 207, 331, 383). Infection occurs when *H. capsulatum* conidia are inhaled, so activities such as mining, speleology, construction, and agriculture are associated with an increased risk of disease (178). Pulmonary infection with *H. capsulatum* is generally asymptomatic; only an estimated 0.5% of infected persons will develop symptomatic disease (388). Most clinically apparent acute infections are mild and self-limited and have nonspecific symptoms such as fever, chills, anorexia, cough, and chest pain, often accompanied by intrathoracic lymphadenopathy (388). Cavitory disease may be a manifestation of acute infection or chronic disease. In one large outbreak in Indianapolis, Indiana, 62/741 (8.4%) patients with symptomatic acute histoplasmosis had cavitation detected by plain chest radiographs. Compared with patients without cavitation, patients with cavitation were more likely to be older, white males with a prior history of chronic lung disease or immunosuppression (389). Cavities were most commonly located in the upper lobes and accompanied by infiltrates and pleural thickening. Another review of cases of pulmonary histoplasmosis presenting to the Mayo Clinic in Rochester, Minnesota, from 1964 to 1974 reported that only 5/269 (1.8%) patients had pulmonary cavitation (72). The chronicity of infection in the Mayo Clinic series was not reported. Among patients with chronic pulmonary histoplasmosis, cavitation was

present on plain radiographs in 33 to 68% of cases (61, 182, 331). Disseminated histoplasmosis, which usually occurs in immunocompromised hosts (particularly persons with advanced human immunodeficiency virus infection), usually does not cause cavitory lung lesions. For example, in one series of patients with advanced human immunodeficiency virus and disseminated histoplasmosis, 23/50 (46%) had abnormal plain chest radiographs with nodules or infiltrates, but none had cavities (71).

Blastomycosis. Pulmonary blastomycosis, caused by the dimorphic fungus *Blastomyces dermatitidis*, is endemic to north central United States and southern central Canada, with somewhat lower-level endemicity in the southeastern United States (62, 177). Although it is referred to as North American blastomycosis, endemic disease has been reported in Africa, India, South America, and Israel (42). Similar to the other endemic mycoses, blastomycosis is found in the soil and causes infection when the soil is disturbed and the fungus is inhaled (327). Blastomycosis most commonly afflicts immunocompetent hosts, although persons with diabetes mellitus seem to be disproportionately affected (39, 78, 374). The lungs are the most common site of disease, with pulmonary involvement reported in 60 to 93% of cases (78, 177, 374). A relatively high proportion (17 to 26%) of patients with pulmonary disease will have concurrent extrapulmonary involvement, particularly cutaneous or bone infection (78, 293, 374). The spectrum of pulmonary disease ranges from acute and often self-limited disease to chronic disease, which may last for years. Acute illness frequently presents with a relatively sudden onset of fever and cough, accompanied by alveolar infiltrates and occasionally nodular densities detected by plain chest radiography. In some cases, the illness resolves without treatment in 1 to 2 months (306). Cavitation is uncommonly (11% in one study) noted in acute disease (293). Chronic pulmonary blastomycosis most commonly appears as an infiltrate on plain chest radiographs, although appearance as a lung mass is also frequently encountered. A miliary pattern similar to that of miliary tuberculosis is seen in up to 11% of cases (34, 335, 346). Cavitation has been noted on plain chest radiography in 6 to 37% of cases of chronic blastomycosis (34, 143, 177, 293, 335, 374). Computed tomography findings are similar to those of plain radiography, with a mixture of infiltrates, nodules, and mass-like abnormalities with or without cavitation. For example, one study of computed tomography in 16 patients with pulmonary blastomycosis revealed that 14 patients (88%) had air bronchograms, 14 (88%) had at least one mass >2 cm in diameter, 12 (75%) had nodules <2 cm in diameter, 9 (56%) had consolidation, and 2 (13%) had cavities (394).

Coccidioidomycosis. Coccidioidomycosis is a term that indicates disease caused by fungi belonging to the genus *Coccidioides*. Two phenotypically indistinguishable species have been associated with human disease: *Coccidioides immitis*, which has been isolated from the San Joaquin Valley in California as well as from southern California and Mexico, and *Coccidioides posadasii*, which has been isolated throughout the southwestern United States (Arizona and southern California), Mexico, and South America (111). *Coccidioides* species live in the soil, and infection is hypothesized to occur through the inhalation of arthroconidia present in soil dust. Supporting this hypothesis, infection rates in areas of endemicity strongly correlate

with ambient dust levels and antecedent rainfall, with bimodal peaks during June to July and October to November (69, 82, 289, 358). Persons who have significant exposure to soil or dust in areas of endemicity, such as military recruits in desert training, are at higher risk for infection with *Coccidioides* than the general population (82). Clinical disease occurs in only about 40% of infected persons and in most cases presents as flu-like symptoms that resolve without medical intervention (56). Persons belonging to specific racial/ethnic groups, particularly Filipinos and African Americans, are at elevated risk to develop severe, disseminated disease after infection. Persons with immunocompromising conditions including diabetes mellitus, malignancy, corticosteroid treatment, pregnancy (especially third trimester) (80), or human immunodeficiency virus infection are also at relatively high risk of developing disease after infection (56, 210, 320, 326).

The most common plain radiographic finding of acute pulmonary coccidioidomycosis is a localized pulmonary infiltrate, which is seen in approximately 50 to 70% of cases (134, 387). Pleural effusion, multiple nodules, and mediastinal lymphadenopathy are also commonly present. Between 1 and 7% of patients with symptomatic coccidioidomycosis, especially those who are immunocompromised, will develop disseminated disease; cavities are uncommon in this setting (81, 326). Cavitation has been noted in 13 to 15% of cases; the cavities can be thin walled or thick walled, and often, only a single cavity is present. Cavities may persist for years in asymptomatic persons but can resolve spontaneously without antifungal therapy in many cases; in one older series, 50% resolved within 2 years without treatment (160). A small proportion of patients may develop chronic fibrocavitary disease that clinically resembles tuberculosis. Persons with diabetes and symptomatic coccidioidomycosis are more likely to demonstrate cavitation than nondiabetic patients. In one study of 329 patients, 34% of diabetic patients with coccidioidomycosis had cavities, compared with 12% of nondiabetic patients, a statistically significant difference (326). Furthermore, among diabetics, those with worse blood glucose control had a higher risk of both cavitory lung disease and relapse after treatment. Patients with cavitory disease may develop bacterial superinfection, or cavities may rupture, causing empyema, pneumothorax, or bronchopleural fistula (107, 241).

Paracoccidioidomycosis. *Paracoccidioides brasiliensis* is the most common fungal species associated with endemic mycosis in Latin America. Infection with *P. brasiliensis* is endemic in a region extending from southern Mexico to Argentina (25, 324). Although its exact ecological niche has not been defined, disease incidence correlates with soil type and yearly precipitation, so soil exposure probably plays a key role in infection (37, 336, 337).

Infection is presumed to occur when conidia are aerosolized and inhaled, with subsequent conversion to the yeast form that disseminates in the host (125). Interestingly, estrogen levels in the host may inhibit conversion from the inhaled mycelial form to the yeast form; this hormonal effect may account for the marked male predominance of clinical disease after puberty (310). Acute infection may be asymptomatic or may be characterized by flu-like symptoms with or without thoracic lymphadenopathy; rarely, severe acute disease occurs with interstitial lung changes and respiratory failure (20). Chronic infection

most commonly presents with mucocutaneous lesions, slowly progressive pulmonary disease, or both (125, 221). Patients with chronic pulmonary paracoccidioidomycosis may have no pulmonary symptoms or only a chronic cough; fever and weight loss are less common (221). Infiltrates, usually interstitial, are the manifestation most frequently detected by plain chest radiography (362), but cavities in 17 to 36% of patients and subpleural bullae in 43% of patients have been noted (98, 221). Computed tomography most commonly reveals interlobular septal thickening, ground-glass opacities, and nodules. Traction bronchiectasis and paracatricial emphysema are also frequently observed. Cavitation is frequently observed within these nodules, with one study reporting cavitation in 33/77 untreated patients (43%) with pulmonary *P. brasiliensis* disease (344) and another reporting cavitation in 6/16 patients (37%) who had been treated for less than 3 months (117). As paracoccidioidomycosis occurs in areas where *M. tuberculosis* is endemic, concurrent infection with both *P. brasiliensis* and *M. tuberculosis* is not uncommonly reported (98); culturing respiratory specimens for mycobacteria is therefore advisable for patients with suspected *P. brasiliensis* infection.

Cryptococcosis. *Cryptococcus neoformans* is a ubiquitous yeast that is commonly found in soil, especially in association with pigeon droppings (250). Infection usually occurs via the inhalation of soil aerosols, although rare cases of disease due to percutaneous inoculation have been reported (379). The clinical manifestations of cryptococcal disease depend on the host. Disseminated disease, often associated with meningitis, is the most common presentation among persons with compromised immune systems due to malignancy, human immunodeficiency virus, corticosteroids, or transplantation (9, 63, 287, 300, 377). Pulmonary disease is the predominant presentation among immunocompetent hosts, although 50 to 80% of those who develop clinically symptomatic pulmonary disease are immunocompromised (187, 276).

Presentation of pulmonary cryptococcosis varies with the immune status of the patient. Immunocompetent hosts frequently present with asymptomatic chest radiographic abnormalities or a chronic cough. Immunocompromised hosts usually present with symptoms including cough, fever, dyspnea, and chest pain. Immunocompromised hosts also often have extrapulmonary manifestations of disease such as skin lesions, meningeal signs, or urinary tract symptoms (52, 197, 276, 403). Similarly, the chest radiographic findings vary with immune status. The most common plain radiographic findings in immunocompetent patients are focal infiltrates and pulmonary nodules. The finding of a single pulmonary nodule or mass is not uncommon among immunocompetent patients with cryptococcal infection (187, 276, 316, 403). Computed tomography similarly reveals one or more pulmonary nodules and/or areas of consolidation. Cavitation may occur within nodules or areas of infiltrate and has been noted in 14 to 21% of plain chest radiographs and 10 to 42% of computed tomography scans of immunocompetent patients with cryptococcal infection (52, 114, 187, 218, 271, 276, 403). Immunocompromised patients with pulmonary cryptococcal infection will also commonly have consolidation, hilar lymphadenopathy, and multiple pulmonary nodules, while solitary pulmonary nodules are less often encountered (187, 249, 384). At least one study demonstrated a significantly higher frequency of cavitation by lung computed

tomography among immunocompromised patients with cryptococcal lung infection (62.5%) than among immunocompetent patients (15.4%), but none of the immunocompromised patients in that study had human immunodeficiency virus infection (52). On the whole, cavitation appears to be more common among persons with mild to moderate immune compromise, such as that caused by diabetes, cirrhosis, or corticosteroid therapy, than among immunocompetent hosts (2, 187, 192). However, persons with severe immune compromise due to human immunodeficiency virus infection rarely have cavitary pulmonary cryptococcal infection; interstitial infiltrates and hilar lymphadenopathy are more common in this patient population (249, 384).

Penicillium. *Penicillium marneffei* is a dimorphic fungus that is endemic to Southeast Asia, especially areas of northern Thailand (351), with some cases arising in Hong Kong (51), Taiwan (350), northeastern India (232, 340), and southern China (88). *P. marneffei* is a soil saprophyte that is believed to enter the body via inhalation or ingestion, and occupational soil exposure is independently associated with *P. marneffei* disease among persons with advanced human immunodeficiency virus infection in Thailand (53). Prior to the human immunodeficiency virus epidemic, reported cases of penicilliosis were uncommon. Among persons infected with human immunodeficiency virus, however, it is quite common; in the mid-1990s, disseminated *P. marneffei* was the third most common opportunistic infection in human immunodeficiency virus-infected patients in northern Thailand, after extrapulmonary tuberculosis and cryptococcal meningitis (352). Penicilliosis afflicts primarily persons with advanced human immunodeficiency virus infection (CD4⁺ T-lymphocyte count of less than 100 cells/mm³), and the concurrent diagnosis of other opportunistic infections (e.g., cryptococcal infection, salmonellosis, and tuberculosis) and penicilliosis is not uncommon (86, 352). In addition, penicilliosis is increasingly being diagnosed in immunocompromised travelers returning from these areas of endemicity (10, 41, 173, 311). Penicilliosis is also an emerging infection in other immunocompromised patients such as those with hematological malignancies (86, 397, 398), corticosteroid use (219, 277), or organ transplantation (50). Penicilliosis has rarely been reported in hosts with a healthy immune system (168, 323).

Penicilliosis presents with nonspecific symptoms such as fever, weight loss, and cough (256). Disease usually represents disseminated infection and may manifest with generalized lymphadenopathy, hepatomegaly, splenomegaly, skin lesions, pulmonary findings, and anemia (245). Pulmonary involvement is common in *P. marneffei* disease: in the largest published series (92 Thai subjects with concurrent human immunodeficiency virus infection), 49% had cough, and 33% had abnormal chest radiographs. The most common plain chest radiographic patterns in this study were diffuse reticulonodular and localized alveolar lesions; no cavities were noted (352). However, a smaller study of Taiwanese patients with penicilliosis and advanced human immunodeficiency virus infection reported cavities on plain chest radiographs for 9/26 (34.6%) patients (350), and other small case series have also described cavitary lesions (54).

Pneumocystis jiroveci. *Pneumocystis jiroveci*, recently reclassified as a fungus, was initially identified as being a rare cause of

pneumonia in malnourished and premature infants in the 1950s (128). However, with the onset of the human immunodeficiency virus epidemic, *P. jiroveci* pneumonia incidence rose dramatically, and it continues to be one of the most common opportunistic illnesses in human immunodeficiency virus-infected persons (259). Other immunocompromised persons are also at risk for *P. jiroveci* pneumonia, including persons with the following risk factors: solid-organ or stem cell transplant; hematologic and solid malignancies; chronic, high-dose corticosteroid use; and use of immunomodulators such as methotrexate or tumor necrosis factor alpha antagonists (85, 126, 161, 174, 179, 313, 363, 410). *P. jiroveci* pneumonia in individuals with no known immune compromise has been reported, but this is a very rare phenomenon (40). Little is known about the source of human infection with *P. jiroveci*, although an environmental reservoir and person-to-person transmission are both considered to be possible (85, 246, 373, 396).

Human immunodeficiency virus-infected patients with *P. jiroveci* pneumonia often present subacutely with one or more of a classic triad of symptoms: fever, dry cough, and dyspnea (278). *P. jiroveci* pneumonia tends to present more acutely among patients with other causes of immunosuppression (200, 288). Plain chest radiography most commonly demonstrates bilateral alveolar or interstitial infiltrates (87, 363), but normal chest radiographs have been found for up to 39% of human immunodeficiency virus-infected patients (284). Spontaneous pneumothorax is a relatively common complication and may be related to subpleural cystic lesions (87). Cavities seen on plain radiographs are usually described as being thin walled or cystic (109) and have been reported in 2 to 6.7% of human immunodeficiency virus-infected patients (87, 329). Cavitation is a rare finding among other patients with *P. jiroveci* pneumonia, with no cavities/cysts described in three moderately large series of patients without human immunodeficiency virus infection (288, 363, 378). Thicker-walled cavities have rarely been reported in association with *P. jiroveci* pneumonia (23, 108, 193). Cavitory lesions are more easily observed using computed tomography, with thin-walled cavities noted in 21 to 31% (116, 151) and thicker-walled cavities noted in up to 6% of human immunodeficiency virus-infected patients (116).

Miscellaneous fungi. Multiple other fungal species have been associated with cavitory pulmonary disease. *Sporothrix schenckii* is usually associated with cutaneous disease, but a few cases of cavitory pulmonary disease in immunocompetent hosts have been reported (285, 303). Disease is generally chronic and may extend over decades, and delayed diagnosis is the norm because of a failure to consider this rare pulmonary pathogen. Dematiaceous molds such as *Ochroconis* have rarely been associated with chronic, cavitory lung disease in immunocompetent hosts, usually in the setting of occupational exposure to aerosols from organic matter (280). *Scedosporium apiospermum* has also rarely been associated with cavitory disease in immunocompromised hosts (269, 409).

Parasites

Echinococcus. *Echinococcus granulosus*, a cestode tapeworm that lives predominantly in dogs, causes cystic echinococcosis (132). Infection occurs worldwide, but prevalence is highest in Mediterranean countries, South America, Australia, New Zea-

land, and Turkey (66, 333). Infection occurs when humans ingest soil contaminated with dog feces that contain *E. granulosus* eggs. The eggs mature into larvae in the intestine and subsequently travel through the bloodstream, eventually forming a cyst in an end organ (242). The liver is the most commonly affected end organ, followed by the lung in approximately 10 to 30% of cases (27, 97, 132, 139, 380). Lung cysts usually appear as homogeneous masses by plain chest radiography, but if air penetrates between the cyst walls or into the cyst, a cavitory appearance may result. This appearance has been given a number of names in the radiology literature (e.g., “crescent sign,” “meniscus sign,” and “water lily sign”), but these signs are not specific for echinococcal disease. Furthermore, bacterial superinfection of an existing cyst may also produce a cavitory appearance (27, 380). Patients with *E. granulosus* pulmonary cysts are usually asymptomatic but may present with a chronic cough. Hemoptysis, fever, and chest pain are less common complaints, and a rare but particularly striking mode of presentation is coughing out of the parasite membranes, known as “vomica” in older literature (15, 229, 361). A cavitory appearance in the setting of *E. granulosus* infection is probably more commonly associated with symptomatic disease, as it indicates a disruption of the integrity of the cyst wall.

E. multilocularis is the other major species of *Echinococcus* of clinical relevance to humans. It is endemic in central Europe, Asia, and Alaska (31, 317, 392). The fox is the definitive host for *E. multilocularis*, and transmission occurs in association with human encroachment into fox habitats, resulting in the ingestion of soil contaminated with fox feces containing *E. multilocularis* eggs (242). As foxes mix with domestic animals, transmission can be propagated by domestic dogs as well. Similar to *E. granulosus*, the eggs mature into larvae in the intestine and migrate through the bloodstream to form cysts. *E. multilocularis* affects the liver in over 90% of cases, with only about 10% of cysts located in the lung (132, 367). Liver cysts are usually asymptomatic, and most disease is probably not detected in the lifetime of the host. For example, in one area of endemicity (south Gansu province, China), the prevalence of typical *E. multilocularis* liver cysts among asymptomatic persons has been reported to be as high as 3.4% (16). Pulmonary disease appears as multiple circular opacities by plain radiography (367), and as with *E. granulosus*, air may rarely penetrate a cyst, resulting in a cavitory appearance. As *E. multilocularis* pulmonary disease is so rarely reported, the prevalence of lung cavities among persons with *E. multilocularis* disease is probably very low.

Paragonimiasis. Paragonimiasis is a parasitic infection caused by one of over 40 species of trematodes in the genus *Paragonimus* (209); the most commonly mentioned species in the medical literature is *Paragonimus westermani*. Infection occurs when humans eat infected crustaceans (usually crabs or crayfish) containing metacercariae. Cases have also been reported after undercooked meat from animals that are infected has been eaten. The metacercariae penetrate the duodenum and migrate through the diaphragm, and they mature into adult flukes in the lung. In the lung, the flukes lay eggs, which are expectorated in the sputum or excreted in feces; if the eggs reach fresh water, they hatch into larvae (miracidium) that infect snails. Eventually cercariae leave the snail, infecting

TABLE 1. Radiographic, epidemiological, and patient characteristics that aid in the differential diagnosis of a pulmonary cavitary lesion

Organism	Radiographical findings	Epidemiology	Patient characteristics, comorbidities, and/or risk factors ^a
Bacteria			
<i>Actinomyces</i> spp.	Acute: airspace disease mass, empyema, wavy periosteal reaction involving ribs adjacent to site of pulmonary or pleural involvement; chronic: abscess, cavitation	Normal inhabitant of oral cavity, gastrointestinal tract, and female reproductive tract	Male predominance, poor oral hygiene
<i>Burkholderia pseudomallei</i>	Acute: nodular infiltrates; subacute: cavity formation in upper lobes; chronic: cavity formation in upper lobes	Found in water and soil in the tropics; endemic primarily in southeast Asia and northern Australia; may occur sporadically in temperate zones	Alcoholism, diabetes mellitus, chronic renal failure, occupational exposure, thalassemia
<i>Klebsiella</i> spp.	Bulging interlobar fissures, unilateral/bilateral infiltrates, abscess, cavitation	Ubiquitous organism; nosocomial and community acquisition	Alcoholism, corticosteroid use, hematologic malignancy, male predominance
<i>Nocardia</i> spp.	Lobar consolidation, nodular infiltrate, solitary mass, cavitation	Ubiquitous soil organism	Chronic obstructive pulmonary disease, corticosteroid use, HIV/AIDS (rare), malignancy, posttransplant
<i>Rhodococcus equi</i>	Consolidation, nodular infiltrate, cavitation, pleural effusion, empyema	Zoonosis that affects grazing animals; exposure to domesticated animals such as horses and pigs may play a role in some infections	Alcoholism, chronic renal failure, diabetes mellitus, hematologic malignancy, HIV/AIDS, posttransplant, rheumatoid arthritis
<i>Salmonella</i> spp. (nontyphoid)	Lobar infiltrate, abscess, nodular infiltrate, cavitary lesion	Common in nature and associated with chickens and pigs; human infection occurs through contaminated food products	Alcoholism, corticosteroid use, diabetes mellitus, HIV/AIDS, malignancy, postgastrectomy, posttransplant
<i>Staphylococcus aureus</i>	Consolidation, pneumatocele, cavity	May be community acquired or nosocomial	Debilitated hospitalized patients, immunocompetent patients with extrapulmonary staphylococcal infection (e.g., skin infection with community-acquired methicillin-resistant <i>S. aureus</i>)
Mycobacteria			
<i>M. tuberculosis</i>	Upper lobe infiltrates, cavity, miliary pattern, tuberculoma, hilar lymphadenopathy	Spread from person to person through inhalation of droplet nuclei; more prevalent in developing countries	Birth or prolonged residence in area of endemicity (developing world), diabetes mellitus, head and neck cancer, hematologic malignancy, HIV/AIDS, immunosuppressive therapy, tumor necrosis factor alpha antagonist use
<i>M. abscessus</i>	Fibronodular bronchiectasis, lobar volume loss, consolidation, cavities	Widely distributed in the environment, especially in bodies/sources of water	Achalasia, cystic fibrosis, previously treated mycobacterial disease
<i>M. avium</i> complex	Bronchiectasis, infiltrate, nodules, apical thickening, scarring, cavities	Widely distributed in the environment, especially in bodies/sources of water	Chronic obstructive pulmonary disease, older and otherwise healthy females, pectus excavatum, scoliosis, white middle-aged men
<i>M. kansasii</i>	Upper lobe, thin-walled cavity, pleural thickening, "drainage area disease," "tail" sign, interstitial infiltrates, hilar adenopathy, nodular/bronchiectatic infiltrates	Found in southern and central United States, southeast England, and Wales; isolated from tap water in areas where disease occurs	Alcoholism, chronic obstructive pulmonary disease, HIV/AIDS, pneumoconiosis, previous mycobacterial disease, white middle-aged men
<i>M. malmoense</i>	Cavity, large-diameter cavity (>6 cm), air-fluid levels, volume loss	Recovered from soil and water; most cases are from Scandinavia and the United Kingdom	Chronic obstructive pulmonary disease, pneumoconiosis
<i>M. xenopi</i>	Nodules, interstitial infiltrates, consolidation, cystic changes, lymphadenopathy, pleural thickening, cavitation	Endemic in Europe (England, Italy) and southern Ontario, Canada; recovered from hot water sources	Alcoholism, chronic obstructive pulmonary disease, diabetes mellitus, HIV/AIDS, organ transplantation, prior gastrectomy

Continued on following page

TABLE 1—Continued

Organism	Radiographical findings	Epidemiology	Patient characteristics, comorbidities, and/or risk factors ^a
Fungi <i>Aspergillus</i> spp.	Invasive aspergillosis: macronodules, consolidation, halo sign, air-crescent sign, cavitation; semi-invasive aspergillosis: progressive or chronic infiltrate, cavity with or without air-crescent sign, aspergilloma; aspergilloma: fungus ball in preexisting cavity	Saprophytic fungi that grow on organic debris; potential environmental exposure for hospitalized high-risk patients	Hematologic malignancy, HIV/AIDS, immunosuppressive therapy, malnutrition, neutropenia, posttransplant, underlying pulmonary disease (asthma, cystic fibrosis) for invasive aspergillosis; alcoholism, chronic obstructive pulmonary disease, collagen vascular disease, diabetes mellitus, low-dose corticosteroid use, malnutrition, pneumoconiosis for semi-invasive; and prior tuberculosis or other cavity-causing disease for aspergilloma
<i>Blastomyces dermatitidis</i>	Acute: patchy alveolar opacities, nodular densities; chronic: fibronodular upper lobe disease, smooth-walled cavities, solitary mass lesion, volume loss, calcification, fibrosis, miliary pattern	Endemic to Mississippi and Ohio River valleys, Great Lakes, and St. Lawrence River region; also found in parts of Mexico, Central and South America, Africa, and the Middle East	Anemia, black race, diabetes mellitus, male gender, outdoor activity, prior history of pneumonia
<i>Coccidioides immitis</i>	Acute: patchy opacities, multilobar consolidation, thick-walled cavities, pleural effusion, hilar lymphadenopathy; chronic: thin-walled cavities, pleural effusion, pneumothorax, single or multiple nodules	Endemic to the southwestern United States and Mexico; may also be associated with occupational exposure (construction, archeological excavation) or extreme weather conditions in an area of endemicity (i.e., dust storm)	Corticosteroid use, diabetes mellitus, HIV/AIDS, malignancy, black or Filipino race/ethnicity, organ transplant
<i>Cryptococcus</i> spp.	Cryptococcoma (solitary or multiple nodules), alveolar consolidation, interstitial pattern, cavitation, lymphadenopathy, pleural effusion	Isolated from soil contaminated by pigeon and chicken excreta; may also be present in contaminated milk, fruit, and wood products	Corticosteroid use, diabetes mellitus, HIV/AIDS, hematologic malignancy, organ transplant, sarcoidosis
<i>Histoplasma capsulatum</i>	Acute: scattered patchy or diffuse interstitial opacities, solitary pulmonary nodule, miliary pattern, hilar or mediastinal lymphadenopathy; chronic: cavitation	Endemic to the Ohio and Mississippi River valleys, Virginia, and Maryland; ubiquitous in nature but grows well in soil that has been enriched by bird excreta	Heavy equipment operators, poultry breeders, spelunkers for acute disease; chronic obstructive pulmonary disease, middle-aged men for chronic disease
<i>Penicillium marneffei</i>	Interstitial infiltrates, alveolar infiltrates, miliary infiltrates, nodular lesions, pleural effusion, cavitation, mass lesions	Endemic to northeast Thailand, Hong Kong, Taiwan, southern China, northeastern India	Autoimmune disorders, corticosteroid use, hematologic malignancy, HIV/AIDS, solid-organ transplant
<i>Pneumocystis jirovecii</i>	Bilateral alveolar/interstitial infiltrates, solitary or multiple nodules, pneumatocele, pneumothorax, cavity, normal	Ubiquitous fungi; believed to be an environmental organism	Autoimmune disorders, corticosteroid use, hematologic malignancy, HIV/AIDS, posttransplantation
Zygomycosis	Focal consolidation, focal mass, cavity, abscess	Found in soil and decaying organic matter	Corticosteroid use, deferoxamine therapy, diabetes mellitus, hematologic malignancy, metabolic acidosis, neutropenia, posttransplant

Continued on following page

TABLE 1—Continued

Organism	Radiographical findings	Epidemiology	Patient characteristics, comorbidities, and/or risk factors ^a
Parasites			
<i>Echinococcus granulosus</i>	Spherical homogenous masses with smooth borders surrounded by normal lung tissue, bullae, calcifications, cavity	Endemic to Mediterranean region, Middle East, Africa, Latin America, southwest United States, southern Europe, largely in livestock-rearing areas; dogs are the definitive host	Healthy host
<i>Echinococcus multilocularis</i>	Multiple homogenous round or oval masses with smooth borders surrounded by normal lung tissue	Endemic to central Europe, Russia, western China, northern Japan, North America, North Africa; may be associated with exposure to foxes or wolves, which are the definitive hosts; domestic dogs and cats may also acquire and transmit infection	Healthy host
<i>Paragonimus westermani</i>	Nodules, mediastinal lymphadenopathy, pleural effusion	Zoonosis that is endemic to Japan, the Korean peninsula, the Philippines, and parts of China; may be acquired through eating freshwater crabs and raw boar meat	Healthy host

^a HIV, human immunodeficiency virus.

crustaceans, and the cycle begins again (375). The disease is highly endemic in Asia, particularly Japan, China, the Korean peninsula, and Southeast Asia, with lower prevalences in Africa and Latin America (170). Untreated disease is often chronic, and on average, patients are symptomatic for several months prior to diagnosis (189). Patients most commonly present with hemoptysis, which may be accompanied by chest pain or fever, and peripheral eosinophilia (170, 263). The most common manifestation of paragonimiasis on plain chest radiographs is a focal infiltrate, but cavitory lesions are common, as are pleural effusions. Cavitation is detected by plain radiography in 8 to 46% of cases (163, 170, 171, 282). Computed tomography demonstrates nodules, which may be single or multiple and are usually subpleural or next to a fissure. Cavitation within one or more of these nodules has been noted in 15 to 59% of cases (163, 189, 263). Computed tomography may also sometimes show an ovoid, soft-tissue-density structure within a cavity, suggesting the presence of a worm, but this finding is present in a relatively small proportion of cases (163).

CAVITARY LUNG DISEASE IN SPECIFIC HOSTS

Human Immunodeficiency Virus

Cavities are a frequent manifestation of opportunistic illness among persons with human immunodeficiency virus infection. Many of the pathogens discussed in this review may cause lung cavities in persons with human immunodeficiency virus, and the spectrum of illnesses associated with cavitory disease has been described well elsewhere (119). The large number of pathological processes associated with cavitation among persons with human immunodeficiency virus infection makes diagnosis difficult based on radiographic studies alone; microbiological and/or pathological studies are almost always neces-

sary. In general, the spectrum of infectious causes of cavities shifts as the CD4⁺ T-lymphocyte count declines. Tuberculosis is a common cause of lung cavities at any CD4⁺ T-lymphocyte count, but the proportion of tuberculosis patients with cavitation decreases as the CD4⁺ T-lymphocyte count declines (18, 222, 262). Furthermore, the relative frequency and diversity of other opportunistic illnesses that cavitate increase at low CD4⁺ T-lymphocyte counts (119). For example, one study of 229 patients with human immunodeficiency virus infection compared findings among patients with bacterial pneumonia, *P. jiroveci* pneumonia, and *M. tuberculosis* pneumonia (329). The prevalences of cavitation in patients with these three infections were 1/94 (1%), 2/99 (2%), and 6/36 (17%), respectively, with median CD4⁺ T-lymphocyte counts of 192, 20, and 96 cells/mm³, respectively. In that study, cavitation was significantly associated with a diagnosis of tuberculosis but had poor sensitivity (17%) and positive predictive value (67%) for tuberculosis. Furthermore, it is common to isolate multiple pathogens from the respiratory tract of persons with advanced human immunodeficiency virus infection and cavitory lung lesions. For example, in one study of 20 persons with human immunodeficiency virus (mean CD4⁺ T-lymphocyte count of 106 cells/mm³), only five had a single bacterial pathogen identified. The other 15 patients had at least two pathogens isolated: 5 with multiple bacterial species and 10 with a bacterial pathogen and another organism (mycobacteria, fungi, *P. jiroveci*, or cytomegalovirus) (13).

Local epidemiology must be taken into consideration when the probability of any particular etiology for a cavitory lung lesion in a person infected with human immunodeficiency virus is assessed. In areas where tuberculosis is endemic, *M. tuberculosis* should always be near the top of the differential diagnosis of a cavitory lung lesion (133). In areas with a low inci-

dence of tuberculosis, other diseases become more common. For example, in a recent population-based survey of opportunistic infections among human immunodeficiency virus-infected persons in the United States, the most common pulmonary infections were *P. jiroveci* (incidence of 2.4/100 person years) and recurrent bacterial pneumonia (incidence of 1.1/100 person years) (349). *P. jiroveci* and bacterial pneumonia are less likely to be associated with cavitory lesions than *M. tuberculosis*, but in areas where tuberculosis is rare, they may account for the majority of cases of cavitory lung disease among human immunodeficiency virus-infected persons. Because of its greater sensitivity for cavities and other lesions, high-resolution computed tomography may be helpful in facilitating the diagnosis of human immunodeficiency virus-infected patients with pulmonary disease (176), but even in a setting where tuberculosis is highly endemic, the predictive value of these studies for a specific diagnosis is moderate at best (279).

Hematologic Malignancy and Transplantation

The spectrum of illnesses associated with cavitory lung lesions is also broad among persons with immunosuppression due to malignancy or transplantation, but some specific illnesses are considerably more common in this population than in persons infected with human immunodeficiency virus. Patients who have received lung transplants frequently have post-transplant pneumonia caused by *Pseudomonas*, *Staphylococcus*, mycobacteria, and *Aspergillus* species, any of which may cause cavities. These infections are particularly common among persons with cystic fibrosis who received a transplant (28). Invasive pulmonary aspergillosis is a common and important infection after hematopoietic stem cell transplant or in the setting of hematological malignancy and neutropenia (14, 47, 334). Invasive aspergillosis is most common in the setting of a mismatched allogeneic hematopoietic stem cell transplant, with a progressively decreasing incidence in matched hematopoietic stem cell transplant, autologous hematopoietic stem cell transplant, and solid-organ transplant recipients (257). *Aspergillus* should always be strongly suspected in the setting of cavitory lesions after transplantation. As an example, in one multi-institutional study of 65 episodes of pneumonia among 307 consecutive heart transplant recipients, 4 patients had cavitory lesions, all of whom had *Aspergillus* (65). Invasive aspergillosis frequently occurs in the early posttransplant period, but with current prophylactic antifungal protocols, invasive aspergillosis is increasingly diagnosed in the later posttransplant period (339). *P. jiroveci* and *Nocardia* infections are also relatively common causes of lung infection among patients with hematological malignancy or posttransplantation, but the routine use of trimethoprim-sulfamethoxazole for *Pneumocystis* prophylaxis and the prevention of cytomegalovirus disease (a disease that increases the risk for other infectious complications) (295) have significantly reduced the frequency of *Pneumocystis* and *Nocardia* lung infection in these patient populations (253). Of course, many of the pathogens discussed in this review can present as cavitory lesions in patients with hematological malignancy or transplants, so aggressive microbiological sampling, including tissue specimens, where possible, and appropriate testing (e.g., culturing for fungi and mycobacteria) are essential.

TABLE 2. Clinical and epidemiological factors associated with specific etiologies of cavitory pulmonary disease

Clinical or epidemiological factor	Potential cause of cavitory pulmonary disease
Acute onset of disease.....	Pulmonary embolism (septic or aseptic) Necrotizing bacterial pneumonia
Alcohol abuse	<i>Actinomyces</i> spp. <i>Klebsiella pneumoniae</i> <i>Mycobacterium tuberculosis</i> Nontuberculous mycobacteria
Diabetes.....	Blastomycosis Coccidioidomycosis <i>Mycobacterium tuberculosis</i> Zygomycosis
Geographical exposure	
Africa	Blastomycosis <i>Cryptococcus</i> spp. (especially <i>C. gattii</i>) <i>Mycobacterium tuberculosis</i> <i>Paragonimus westermani</i>
Australia	<i>Burkholderia pseudomallei</i> <i>Echinococcus granulosus</i>
Asia	<i>Echinococcus multilocularis</i> <i>Paragonimus westermani</i> <i>Mycobacterium tuberculosis</i>
Latin America.....	Blastomycosis Coccidioidomycosis <i>Echinococcus granulosus</i> Histoplasmosis (Mexico/Central America) <i>Mycobacterium tuberculosis</i> Paracoccidioidomycosis
Southeast Asia	<i>Burkholderia pseudomallei</i> <i>Paragonimus westermani</i> <i>Penicillium marneffe</i>
United States	
Midwest.....	Blastomycosis Histoplasmosis
Southwest.....	Coccidioidomycosis
Human immunodeficiency virus.....	Kaposi's sarcoma Primary pulmonary lymphoma Coccidioidomycosis <i>Cryptococcus</i> spp. <i>Penicillium marneffe</i> <i>Pneumocystis jiroveci</i> <i>Rhodococcus equi</i> <i>Salmonella</i> spp. <i>Mycobacterium kansasii</i> <i>Mycobacterium tuberculosis</i>
Immunocompromised host (human immunodeficiency virus negative).....	Aseptic pulmonary embolism <i>Aspergillus</i> spp. Coccidioidomycosis <i>Cryptococcus neoformans</i> <i>Mycobacterium tuberculosis</i> <i>Nocardia</i> spp. <i>Pseudomonas aeruginosa</i> <i>Pneumocystis jiroveci</i> <i>Staphylococcus aureus</i> Zygomycosis
Nosocomial infection	<i>Staphylococcus aureus</i> <i>Klebsiella pneumoniae</i>
Smoking	Primary lung cancer Pulmonary Langerhans cell histiocytosis <i>Klebsiella pneumoniae</i> <i>Mycobacterium tuberculosis</i> Nontuberculous mycobacteria
Underlying lung disease.....	Nontuberculous mycobacteria <i>Nocardia</i> spp.
Zoonosis	
Dogs and other canids.....	<i>Echinococcus</i> spp.
Crustaceans	<i>Paragonimus westermani</i>
Livestock.....	<i>Rhodococcus equi</i>

CONCLUSIONS

The spectrum of infectious and noninfectious processes associated with pulmonary cavities is daunting, but narrowing the differential diagnosis can be facilitated by a careful review of the patient's history and radiographic data (Table 1). First, an understanding of the immune status of the host is vital to assessing the relative probability of a given process producing lung cavities. Hosts with different types of immunosuppression (e.g., transplantation versus human immunodeficiency virus) will have different relative predilections to have cavitary lung lesions caused by different pathogenic processes. Second, many infectious processes are associated with specific exposures, and elucidation of the exposure history can often serve to increase or reduce the likelihood of a given underlying infection (Table 2). Third, associated clinical and radiographic features may be helpful in moving a given process to the top of the differential. For example, the presence of cavitation in association with right middle lobe and lingular bronchiectasis and nodules often suggests nontuberculous mycobacterial disease. Radiographic studies are rarely definitive, however, and must be supplemented by focused microbiological and pathological evaluations of affected sites, considering likely pathogens. In many settings, culturing respiratory specimens obtained from patients with cavitary lung lesions for bacteria, mycobacteria, and fungi is an appropriate first step in evaluating the etiology of a cavity. Appropriate supplemental testing, including blood cultures, antigen tests, antibody tests, and nucleic acid amplification, is useful when such testing is focused on likely processes and the test characteristics are taken into consideration. Given the broad spectrum of pathogens associated with pulmonary cavities, clinical prediction rules are unlikely to be accurate enough in most diagnostic settings to avoid the need for microbiological and/or pathological confirmation, and clinicians should not be afraid to pursue a tissue diagnosis when warranted.

ACKNOWLEDGMENTS

We gratefully acknowledge Gary Cox, David Holland, and Tahaniyat Lalani for critical review of the manuscript.

L.B.G. received salary support from National Institutes of Health AIDS training grant 5T32AI007392. J.E.S. received salary support from National Institutes of Health K23 grant AI051409.

REFERENCES

1. Abehsera, M., D. Valeyre, P. Grenier, H. Jalliet, J. P. Battesti, and M. W. Brauner. 2000. Sarcoidosis with pulmonary fibrosis: CT patterns and correlation with pulmonary function. *Am. J. Roentgenol.* **174**:1751–1757.
2. Aberg, J. A., L. M. Mundy, and W. G. Powderly. 1999. Pulmonary cryptococcosis in patients without HIV infection. *Chest* **115**:734–740.
3. Aberle, D. R., G. Gamsu, and D. Lynch. 1990. Thoracic manifestations of Wegener granulomatosis: diagnosis and course. *Radiology* **174**:703–709.
4. Abramson, S. 2001. The air crescent sign. *Radiology* **218**:230–232.
5. Aguado, J. M., G. Obeso, J. J. Cabanillas, M. Fernandez-Guerrero, and J. Ales. 1990. Pleuropulmonary infections due to nontyphoid strains of *Salmonella*. *Arch. Intern. Med.* **150**:54–56.
6. Akbari, J. G., P. K. Varma, P. K. Neema, M. U. Menon, and K. S. Neelakandhan. 2005. Clinical profile and surgical outcome for pulmonary aspergilloma: a single center experience. *Ann. Thorac. Surg.* **80**:1067–1072.
7. Aktogu, S., G. Yuncu, H. Halilcolar, S. Ermete, and T. Buduneli. 1996. Bronchogenic cysts: clinicopathological presentation and treatment. *Eur. Respir. J.* **9**:2017–2021.
8. American Thoracic Society. 2000. Targeted tuberculin testing and treatment of latent tuberculosis infection. *MMWR Recomm. Rep.* **49**:1–51.
9. Antinori, S., L. Galimberti, C. Magni, A. Casella, L. Vago, F. Mainini, M. Piazza, M. Nebuloni, M. Fasan, C. Bonaccorso, G. M. Vigevani, A. Cargnel, M. Moroni, and A. Ridolfo. 2001. *Cryptococcus neoformans* infection in a cohort of Italian AIDS patients: natural history, early prognostic parameters, and autopsy findings. *Eur. J. Clin. Microbiol. Infect. Dis.* **20**:711–717.
10. Antinori, S., E. Gianelli, C. Bonaccorso, A. L. Ridolfo, F. Croce, S. Sollima, and C. Parravicini. 2006. Disseminated *Penicillium marneffii* infection in an HIV-positive Italian patient and a review of cases reported outside endemic regions. *J. Travel Med.* **13**:181–188.
11. Apotheloz, C., and C. Regamey. 1996. Disseminated infection due to *Actinomyces meyeri*: case report and review. *Clin. Infect. Dis.* **22**:621–625.
12. Aquino, S. L., S. T. Kee, M. L. Warnock, and G. Gamsu. 1994. Pulmonary aspergillosis: imaging findings with pathologic correlation. *Am. J. Roentgenol.* **163**:811–815.
13. Aviram, G., J. E. Fishman, and M. Sagar. 2001. Cavitary lung disease in AIDS: etiologies and correlation with immune status. *AIDS Patient Care STDs* **15**:353–361.
14. Baddley, J. W., T. P. Stroud, D. Salzman, and P. G. Pappas. 2001. Invasive mold infections in allogeneic bone marrow transplant recipients. *Clin. Infect. Dis.* **32**:1319–1324.
15. Balikian, J. P., and F. F. Mudarris. 1974. Hydatid disease of the lungs. A roentgenologic study of 50 cases. *Am. J. Roentgenol. Radium Ther. Nucl. Med.* **122**:692–707.
16. Bartholomot, G., D. A. Vuitton, S. Harraga, D. Z. Shi, P. Girardoux, G. Barnish, Y. H. Wang, C. N. MacPherson, and P. S. Craig. 2002. Combined ultrasound and serologic screening for hepatic alveolar echinococcosis in central China. *Am. J. Trop. Med. Hyg.* **66**:23–29.
17. Bartlett, J. G. 1993. Anaerobic bacterial infections of the lung and pleural space. *Clin. Infect. Dis.* **16**(Suppl. 4):S248–S255.
18. Batungwanayo, J., H. Taelman, R. Dhote, J. Bogaerts, S. Allen, and P. Van de Perre. 1992. Pulmonary tuberculosis in Kigali, Rwanda. Impact of human immunodeficiency virus infection on clinical and radiographic presentation. *Am. Rev. Respir. Dis.* **146**:53–56.
19. Baughman, R. P., A. S. Teirstein, M. A. Judson, M. D. Rossman, H. Yeager, Jr., E. A. Bresnitz, L. DePalo, G. Hunninghake, M. C. Iannuzzi, C. J. Johns, G. McLennan, D. R. Moller, L. S. Newman, D. L. Rabin, C. Rose, B. Rybicki, S. E. Weinberger, M. L. Terrin, G. L. Knatterud, and R. Cherniak. 2001. Clinical characteristics of patients in a case control study of sarcoidosis. *Am. J. Respir. Crit. Care Med.* **164**:1885–1889.
20. Benard, G., J. Kavakama, M. J. Mendes-Giannini, A. Kono, A. J. Duarte, and M. A. Shikanai-Yasuda. 2005. Contribution to the natural history of paracoccidioidomycosis: identification of the primary pulmonary infection in the severe acute form of the disease—a case report. *Clin. Infect. Dis.* **40**:e1–e4.
21. Benator, D., M. Bhattacharya, L. Bozeman, W. Burman, A. Cantazaro, R. Chaisson, F. Gordin, C. R. Horsburgh, J. Horton, A. Khan, C. Lahart, B. Metchock, C. Pachucki, L. Stanton, A. Vernon, M. E. Villarino, Y. C. Wang, M. Weiner, and S. Weis. 2002. Rifampentine and isoniazid once a week versus rifampicin and isoniazid twice a week for treatment of drug-susceptible pulmonary tuberculosis in HIV-negative patients: a randomised clinical trial. *Lancet* **360**:528–534.
22. Bennhoff, D. F. 1984. Actinomycosis: diagnostic and therapeutic considerations and a review of 32 cases. *Laryngoscope* **94**:1198–1217.
23. Blackmore, T. K., J. P. Slavotinek, and D. L. Gordon. 1994. Cystic pulmonary lesions in *Pneumocystis carinii* infection. *Australas. Radiol.* **38**:138–140.
24. Bloch, K. C., L. Zwerling, M. J. Pletcher, J. A. Hahn, J. L. Gerberding, S. M. Ostroff, D. J. Vugia, and A. L. Reingold. 1998. Incidence and clinical implications of isolation of *Mycobacterium kansasii*: results of a 5-year, population-based study. *Ann. Intern. Med.* **129**:698–704.
25. Blotta, M. H., R. L. Mamoni, S. J. Oliveira, S. A. Nouer, P. M. Papaïorodou, A. Goveia, and Z. P. Camargo. 1999. Endemic regions of paracoccidioidomycosis in Brazil: a clinical and epidemiologic study of 584 cases in the southeast region. *Am. J. Trop. Med. Hyg.* **61**:390–394.
26. Blum, U., M. Windfuhr, C. Buitrago-Tellez, G. Sigmund, E. W. Herbst, and M. Langer. 1994. Invasive pulmonary aspergillosis. MRI, CT, and plain radiographic findings and their contribution for early diagnosis. *Chest* **106**:1156–1161.
27. Bonakdarpour, A. 1967. Echinococcus disease. Report of 112 cases from Iran and a review of 611 cases from the United States. *Am. J. Roentgenol. Radium Ther. Nucl. Med.* **99**:660–667.
28. Bonvillain, R. W., V. G. Valentine, G. Lombard, S. LaPlace, G. Dhillon, and G. Wang. 2007. Post-operative infections in cystic fibrosis and non-cystic fibrosis patients after lung transplantation. *J. Heart Lung Transplant.* **26**:890–897.
29. Brauner, M. W., P. Grenier, D. Mompoin, S. Lenoir, and H. de Cremoux. 1989. Pulmonary sarcoidosis: evaluation with high-resolution CT. *Radiology* **172**:467–471.
30. Brauner, M. W., P. Grenier, M. M. Moulhi, D. Mompoin, and S. Lenoir. 1989. Pulmonary histiocytosis X: evaluation with high-resolution CT. *Radiology* **172**:255–258.
31. Bresson-Hadni, S., J. J. Laplante, D. Lenys, P. Rohmer, B. Gottstein, P. Jacquier, P. Mercet, J. P. Meyer, J. P. Miguet, and D. A. Vuitton. 1994. Seroepidemiologic screening of *Echinococcus multilocularis* infection in a

- European area endemic for alveolar echinococcosis. *Am. J. Trop. Med. Hyg.* **51**:837–846.
32. **British Thoracic Society.** 2001. First randomised trial of treatments for pulmonary disease caused by *M. avium* intracellulare, *M. malmoense*, and *M. xenopi* in HIV negative patients: rifampicin, ethambutol and isoniazid versus rifampicin and ethambutol. *Thorax* **56**:167–172.
 33. **Brown, J. R.** 1973. Human actinomycosis. A study of 181 subjects. *Hum. Pathol.* **4**:319–330.
 34. **Brown, L. R., S. J. Swensen, R. E. Van Scoy, U. B. Prakash, D. T. Coles, and T. V. Colby.** 1991. Roentgenologic features of pulmonary blastomycosis. *Mayo Clin. Proc.* **66**:29–38.
 35. **Brown-Elliott, B. A., J. M. Brown, P. S. Conville, and R. J. Wallace, Jr.** 2006. Clinical and laboratory features of the *Nocardia* spp. based on current molecular taxonomy. *Clin. Microbiol. Rev.* **19**:259–282.
 36. **Buckley, J. A., A. R. Padhani, and J. E. Kuhlman.** 1995. CT features of pulmonary nocardiosis. *J. Comput. Assist. Tomogr.* **19**:726–732.
 37. **Calle, D., D. S. Rosero, L. C. Orozco, D. Camargo, E. Castaneda, and A. Restrepo.** 2001. Paracoccidioidomycosis in Colombia: an ecological study. *Epidemiol. Infect.* **126**:309–315.
 38. **Cannon, J. W.** 2002. Necrotizing clostridial pneumonia: a case report and review of the literature. *Mil. Med.* **167**:85–86.
 39. **Cano, M. V., G. F. Ponce-de-Leon, S. Tippen, M. D. Lindsley, M. Warwick, and R. A. Hajjeh.** 2003. Blastomycosis in Missouri: epidemiology and risk factors for endemic disease. *Epidemiol. Infect.* **131**:907–914.
 40. **Cano, S., F. Capote, A. Pereira, E. Calderon, and J. Castillo.** 1993. Pneumocystis carinii pneumonia in patients without predisposing illnesses. Acute episode and follow-up of five cases. *Chest* **104**:376–381.
 41. **Carey, J., H. Hofflich, R. Amre, J. Protic, and D. C. Perlman.** 2005. Penicillium marneffii infection in an immunocompromised traveler: a case report and literature review. *J. Travel Med.* **12**:291–294.
 42. **Carman, W. F., J. A. Frean, H. H. Crewe-Brown, G. A. Culligan, and C. N. Young.** 1989. Blastomycosis in Africa. A review of known cases diagnosed between 1951 and 1987. *Mycopathologia* **107**:25–32.
 43. **Carpenter, J. L.** 1990. Klebsiella pulmonary infections: occurrence at one medical center and review. *Rev. Infect. Dis.* **12**:672–682.
 44. **Casado, J. L., E. Navas, B. Frutos, A. Moreno, P. Martin, J. M. Hermida, and A. Guerrero.** 1997. Salmonella lung involvement in patients with HIV infection. *Chest* **112**:1197–1201.
 45. **Casserly, I. P., H. M. Fenlon, E. Breatnach, and S. M. Sant.** 1997. Lung findings on high-resolution computed tomography in idiopathic ankylosing spondylitis—correlation with clinical findings, pulmonary function testing and plain radiography. *Br. J. Rheumatol.* **36**:677–682.
 46. **Cervia, J. S., T. A. Caputo, S. D. Davis, and H. W. Murray.** 1990. Septic pulmonary embolism complicating a central venous catheter. *Chest* **98**:1526.
 47. **Chamilos, G., E. M. Marom, R. E. Lewis, M. S. Lionakis, and D. P. Kontoyiannis.** 2005. Predictors of pulmonary zygomycosis versus invasive pulmonary aspergillosis in patients with cancer. *Clin. Infect. Dis.* **41**:60–66.
 48. **Chan, J. C., and T. A. Raffin.** 1991. Salmonella lung abscess complicating Wegener's granulomatosis. *Respir. Med.* **85**:339–341.
 49. **Chan, P. C., L. M. Huang, P. S. Wu, P. Y. Chang, T. T. Yang, C. Y. Lu, P. I. Lee, J. M. Chen, C. Y. Lee, and L. Y. Chang.** 2005. Clinical management and outcome of childhood lung abscess: a 16-year experience. *J. Microbiol. Immunol. Infect.* **38**:183–188.
 50. **Chan, Y. H., K. M. Wong, K. C. Lee, P. C. Kwok, W. L. Chak, K. S. Choi, K. F. Chau, and C. S. Li.** 2004. Pneumonia and mesenteric lymphadenopathy caused by disseminated *Penicillium marneffii* infection in a cadaveric renal transplant recipient. *Transpl. Infect. Dis.* **6**:28–32.
 51. **Chang, K. C., C. K. Chan, K. C. Chow, and C. W. Lam.** 1998. *Penicillium marneffii* infection and solitary pulmonary nodule. *Hong Kong Med. J.* **4**:59–62.
 52. **Chang, W. C., C. Tzao, H. H. Hsu, S. C. Lee, K. L. Huang, H. J. Tung, and C. Y. Chen.** 2006. Pulmonary cryptococcosis: comparison of clinical and radiographic characteristics in immunocompetent and immunocompromised patients. *Chest* **129**:333–340.
 53. **Chariyalertsak, S., T. Sirisanthana, K. Supparatpinoy, J. Praparattanapan, and K. E. Nelson.** 1997. Case-control study of risk factors for *Penicillium marneffii* infection in human immunodeficiency virus-infected patients in northern Thailand. *Clin. Infect. Dis.* **24**:1080–1086.
 54. **Cheng, N. C., W. W. Wong, C. P. Fung, and C. Y. Liu.** 1998. Unusual pulmonary manifestations of disseminated *Penicillium marneffii* infection in three AIDS patients. *Med. Mycol.* **36**:429–432.
 55. **Cheon, J. E., J. G. Im, M. Y. Kim, J. S. Lee, G. M. Choi, and K. M. Yeon.** 1998. Thoracic actinomycosis: CT findings. *Radiology* **209**:229–233.
 56. **Chiller, T. M., J. N. Galgiani, and D. A. Stevens.** 2003. Coccidioidomycosis. *Infect. Dis. Clin. N. Am.* **17**:41–57.
 57. **Chirinos, J. A., D. M. Lichtstein, J. Garcia, and L. J. Tamariz.** 2002. The evolution of Lemierre syndrome: report of 2 cases and review of the literature. *Medicine (Baltimore)* **81**:458–465.
 58. **Chiu, F. T.** 1975. Cavitation in lung cancers. *Aust. N. Z. J. Med.* **5**:523–530.
 59. **Christensen, E. E., G. W. Dietz, C. H. Ahn, J. S. Chapman, R. C. Murry, J. Anderson, and G. A. Hurst.** 1979. Pulmonary manifestations of *Mycobacterium intracellulare*. *Am. J. Roentgenol.* **133**:59–66.
 60. **Christensen, E. E., G. W. Dietz, C. H. Ahn, J. S. Chapman, R. C. Murry, and G. A. Hurst.** 1978. Radiographic manifestations of pulmonary *Mycobacterium kansasii* infections. *Am. J. Roentgenol.* **131**:985–993.
 61. **Christoforidis, A. J.** 1970. Radiologic manifestations of histoplasmosis. *Am. J. Roentgenol. Radium Ther. Nucl. Med.* **109**:478–490.
 62. **Chu, J. H., C. Feudtner, K. Heydon, T. J. Walsh, and T. E. Zaoutis.** 2006. Hospitalizations for endemic mycoses: a population-based national study. *Clin. Infect. Dis.* **42**:822–825.
 63. **Chuck, S. L., and M. A. Sande.** 1989. Infections with *Cryptococcus neoformans* in the acquired immunodeficiency syndrome. *N. Engl. J. Med.* **321**:794–799.
 64. **Chung, M. J., K. S. Lee, W. J. Koh, J. H. Lee, T. S. Kim, O. J. Kwon, and S. Kim.** 2005. Thin-section CT findings of nontuberculous mycobacterial pulmonary diseases: comparison between *Mycobacterium avium*-intracellular complex and *Mycobacterium abscessus* infection. *J. Korean Med. Sci.* **20**:777–783.
 65. **Cisneros, J. M., P. Munoz, J. Torre-Cisneros, M. Gurgui, M. J. Rodriguez-Hernandez, J. M. Aguado, A. Echaniz, et al.** 1998. Pneumonia after heart transplantation: a multi-institutional study. *Clin. Infect. Dis.* **27**:324–331.
 66. **Cohen, H., E. Paolillo, R. Bonifacio, B. Botta, L. Parada, P. Cabrera, K. Snowden, R. Gasser, R. Tessier, L. Dibarboure, H. Wen, J. C. Allan, H. Soto de Alfaro, M. T. Rogan, and P. S. Craig.** 1998. Human cystic echinococcosis in a Uruguayan community: a sonographic, serologic, and epidemiologic study. *Am. J. Trop. Med. Hyg.* **59**:620–627.
 67. **Coke, L. R., and J. C. Dundee.** 1955. Cavitation in bland infarcts of the lung. *Can. Med. Assoc. J.* **72**:907–910.
 68. **Colmegna, I., M. Rodriguez-Barradas, R. Rauch, J. Clarridge, and E. J. Young.** 2003. Disseminated *Actinomyces meyeri* infection resembling lung cancer with brain metastases. *Am. J. Med. Sci.* **326**:152–155.
 69. **Comrie, A. C.** 2005. Climate factors influencing coccidioidomycosis seasonality and outbreaks. *Environ. Health Perspect.* **113**:688–692.
 70. **Conant, E. F., and R. J. Wechsler.** 1992. Actinomycosis and nocardiosis of the lung. *J. Thorac. Imaging* **7**:75–84.
 71. **Conces, D. J., Jr., S. M. Stockberger, R. D. Tarver, and L. J. Wheat.** 1993. Disseminated histoplasmosis in AIDS: findings on chest radiographs. *Am. J. Roentgenol.* **160**:15–19.
 72. **Connell, J. V., and J. R. Muhm.** 1976. Radiographic manifestations of pulmonary histoplasmosis: a 10-year review. *Radiology* **121**:281–285.
 73. **Cook, R. J., R. W. Ashton, G. L. Aughenbaugh, and J. H. Ryu.** 2005. Septic pulmonary embolism: presenting features and clinical course of 14 patients. *Chest* **128**:162–166.
 74. **Corbett, E. L., L. Blumberg, G. J. Churchyard, N. Moloi, K. M. Mallory, T. Clayton, B. G. Williams, R. E. Chaisson, R. J. Hayes, and K. M. De Cock.** 1999. Nontuberculous mycobacteria: defining disease in a prospective cohort of South African miners. *Am. J. Respir. Crit. Care Med.* **160**:15–21.
 75. **Corbett, E. L., B. Marston, G. J. Churchyard, and K. M. De Cock.** 2006. Tuberculosis in sub-Saharan Africa: opportunities, challenges, and change in the era of antiretroviral treatment. *Lancet* **367**:926–937.
 76. **Cordier, J. F., R. Loire, and J. Brune.** 1989. Idiopathic bronchiolitis obliterans organizing pneumonia. Definition of characteristic clinical profiles in a series of 16 patients. *Chest* **96**:999–1004.
 77. **Cordier, J. F., D. Valeyre, L. Guillevin, R. Loire, and J. M. Brechot.** 1990. Pulmonary Wegener's granulomatosis. A clinical and imaging study of 77 cases. *Chest* **97**:906–912.
 78. **Crampton, T. L., R. B. Light, G. M. Berg, M. P. Meyers, G. C. Schroeder, E. S. Hershfield, and J. M. Embil.** 2002. Epidemiology and clinical spectrum of blastomycosis diagnosed at Manitoba hospitals. *Clin. Infect. Dis.* **34**:1310–1316.
 79. **Cronin, S. F., M. H. Abidi, C. J. Shearer, P. H. Chandrasekar, and R. B. Ibrahim.** 2007. *Rhodococcus equi* lung infection in an allogeneic hematopoietic stem cell transplant recipient. *Transpl. Infect. Dis.* **10**:48–51.
 80. **Crum, N. F., and G. Ballon-Landa.** 2006. Coccidioidomycosis in pregnancy: case report and review of the literature. *Am. J. Med.* **119**:993–997.
 81. **Crum, N. F., E. R. Lederman, C. M. Stafford, J. S. Parrish, and M. R. Wallace.** 2004. Coccidioidomycosis: a descriptive survey of a reemerging disease. Clinical characteristics and current controversies. *Medicine (Baltimore)* **83**:149–175.
 82. **Crum, N. F., M. Potter, and D. Pappagianis.** 2004. Seroincidence of coccidioidomycosis during military desert training exercises. *J. Clin. Microbiol.* **42**:4552–4555.
 83. **Curtis, A. M., G. J. Smith, and C. E. Ravin.** 1979. Air crescent sign of invasive aspergillosis. *Radiology* **133**:17–21.
 84. **Danner, P. K., D. R. McFarland, and B. Felson.** 1968. Massive pulmonary gangrene. *Am. J. Roentgenol. Radium Ther. Nucl. Med.* **103**:548–554.
 85. **de Boer, M. G., L. E. Bruijnesteijn van Coppenraet, A. Gaasbeek, S. P. Berger, L. B. Gelinck, H. C. van Houwelingen, P. van den Broek, E. J. Kuijper, F. P. Kroon, and J. P. Vandenbroucke.** 2007. An outbreak of *Pneumocystis jirovecii* pneumonia with 1 predominant genotype among renal transplant recipients: interhuman transmission or a common environmental source? *Clin. Infect. Dis.* **44**:1143–1149.

86. **Deesomchok, A., and S. Tanprawate.** 2006. A 12-case series of *Penicillium marneffei* pneumonia. *J. Med. Assoc. Thai.* **89**:441–447.
87. **DeLorenzo, L. J., C. T. Huang, G. P. Maguire, and D. J. Stone.** 1987. Roentgenographic patterns of *Pneumocystis carinii* pneumonia in 104 patients with AIDS. *Chest* **91**:323–327.
88. **Deng, Z., J. L. Ribas, D. W. Gibson, and D. H. Connor.** 1988. Infections caused by *Penicillium marneffei* in China and Southeast Asia: review of eighteen published cases and report of four more Chinese cases. *Rev. Infect. Dis.* **10**:640–652.
89. **Denning, D. W.** 2001. Chronic forms of pulmonary aspergillosis. *Clin. Microbiol. Infect.* **7**(Suppl. 2):25–31.
90. **Denning, D. W., K. Riniotis, R. Dobrashian, and H. Sambatakou.** 2003. Chronic cavitary and fibrosing pulmonary and pleural aspergillosis: case series, proposed nomenclature change, and review. *Clin. Infect. Dis.* **37**(Suppl. 3):S265–S280.
91. **Dhensiri, T., S. Puapairoj, and W. Sussaengrat.** 1988. Pulmonary melioidosis: clinical-radiologic correlation in 183 cases in northeastern Thailand. *Radiology* **166**:711–715.
92. **Dodd, G. D., and J. J. Boyle.** 1961. Excavating pulmonary metastases. *Am. J. Roentgenol. Radium Ther. Nucl. Med.* **85**:277–293.
93. **Dodd, J. D., C. A. Souza, and N. L. Muller.** 2006. High-resolution MDCT of pulmonary septic embolism: evaluation of the feeding vessel sign. *Am. J. Roentgenol.* **187**:623–629.
94. **Donisi, A., M. G. Suardi, S. Casari, M. Longo, G. P. Cadeo, and G. Carosi.** 1996. *Rhodococcus equi* infection in HIV-infected patients. *AIDS* **10**:359–362.
95. **Donnabella, V., J. Salazar-Schicchi, S. Bonk, B. Hanna, and W. N. Rom.** 2000. Increasing incidence of *Mycobacterium xenopi* at Bellevue hospital: an emerging pathogen or a product of improved laboratory methods? *Chest* **118**:1365–1370.
96. **Donnelly, L. F., and L. A. Klosterman.** 1998. Cavitary necrosis complicating pneumonia in children: sequential findings on chest radiography. *Am. J. Roentgenol.* **171**:253–256.
97. **Donovan, S. M., N. Mickiewicz, R. D. Meyer, and C. B. Panosian.** 1995. Imported echinococcosis in southern California. *Am. J. Trop. Med. Hyg.* **53**:668–671.
98. **dos Santos, J. W., L. C. Severo, N. S. Porto, J. S. Moreira, L. C. da Silva, and J. J. Carmargo.** 1999. Chronic pulmonary paracoccidioidomycosis in the state of Rio Grande do Sul, Brazil. *Mycopathologia* **145**:63–67.
99. **El Maghraoui, A., S. Chaouir, A. Abid, A. Bezza, F. Tabache, L. Achemlal, A. Abouzahir, D. Ghafir, V. Ohayon, and M. I. Archane.** 2004. Lung findings on thoracic high-resolution computed tomography in patients with ankylosing spondylitis. Correlations with disease duration, clinical findings and pulmonary function testing. *Clin. Rheumatol.* **23**:123–128.
100. **El Solh, A. A., J. Nopper, M. R. Abdul-Khoudoud, S. M. Sherif, A. T. Aquilina, and B. J. Grant.** 1998. Clinical and radiographic manifestations of uncommon pulmonary nontuberculous mycobacterial disease in AIDS patients. *Chest* **114**:138–145.
101. **Epler, G. R., T. V. Colby, T. C. McLoud, C. B. Carrington, and E. A. Gaensler.** 1985. Bronchiolitis obliterans organizing pneumonia. *N. Engl. J. Med.* **312**:152–158.
102. **Evans, A. J., A. J. Crisp, A. Colville, S. A. Evans, and I. D. Johnston.** 1993. Pulmonary infections caused by *Mycobacterium mageritense* and *Mycobacterium tuberculosis*: comparison of radiographic features. *Am. J. Roentgenol.* **161**:733–737.
103. **Evans, S. A., A. Colville, A. J. Evans, A. J. Crisp, and I. D. Johnston.** 1996. Pulmonary *Mycobacterium kansasii* infection: comparison of the clinical features, treatment and outcome with pulmonary tuberculosis. *Thorax* **51**:1248–1252.
104. **Fan, K. T., G. J. Whitman, and F. S. Chew.** 1996. Pulmonary zygomyces. *Am. J. Roentgenol.* **167**:946.
105. **Farina, C., P. Boiron, I. Ferrari, F. Provost, and A. Goglio.** 2001. Report of human nocardiosis in Italy between 1993 and 1997. *Eur. J. Epidemiol.* **17**:1019–1022.
106. **Feigin, D. S.** 1986. Nocardiosis of the lung: chest radiographic findings in 21 cases. *Radiology* **159**:9–14.
107. **Feldman, B. S., and L. S. Snyder.** 2001. Primary pulmonary coccidioidomycosis. *Semin. Respir. Infect.* **16**:231–237.
108. **Ferre, C., F. Bagueña, D. Podzamczar, C. Sanchez, P. F. Viladrich, J. Garau, and F. Gudiol.** 1994. Lung cavitation associated with *Pneumocystis carinii* infection in the acquired immunodeficiency syndrome: a report of six cases and review of the literature. *Eur. Respir. J.* **7**:134–139.
109. **Feurestein, I. M., A. Archer, J. M. Pluda, P. S. Francis, J. Falloon, H. Masur, H. I. Pass, and W. D. Travis.** 1990. Thin-walled cavities, cysts, and pneumothorax in *Pneumocystis carinii* pneumonia: further observations with histopathologic correlation. *Radiology* **174**:697–702.
110. **Field, S. K., and R. L. Cowie.** 2006. Lung disease due to the more common nontuberculous mycobacteria. *Chest* **129**:1653–1672.
111. **Fisher, M. C., G. L. Koenig, T. J. White, and J. W. Taylor.** 2002. Molecular and phenotypic description of *Coccidioides posadasii* sp. nov., previously recognized as the non-California population of *Coccidioides immitis*. *Mycologia* **94**:73–84.
112. **Fishman, J. E., D. S. Schwartz, and G. J. Sais.** 1997. *Mycobacterium kansasii* pulmonary infection in patients with AIDS: spectrum of chest radiographic findings. *Radiology* **204**:171–175.
113. **Flynn, M. W. and B. Felson.** 1970. The roentgen manifestations of thoracic actinomycosis. *Am. J. Roentgenol. Radium Ther. Nucl. Med.* **110**:707–716.
114. **Fox, D. L., and N. L. Muller.** 2005. Pulmonary cryptococcosis in immunocompetent patients: CT findings in 12 patients. *Am. J. Roentgenol.* **185**:622–626.
115. **Franquet, T., N. L. Muller, A. Gimenez, S. Martinez, M. Madrid, and P. Domingo.** 2003. Infectious pulmonary nodules in immunocompromised patients: usefulness of computed tomography in predicting their etiology. *J. Comput. Assist. Tomogr.* **27**:461–468.
116. **Fujii, T., T. Nakamura, and A. Iwamoto.** 2007. *Pneumocystis pneumonia* in patients with HIV infection: clinical manifestations, laboratory findings, and radiological features. *J. Infect. Chemother.* **13**:1–7.
117. **Funari, M., J. Kavakama, M. A. Shikanai-Yasuda, L. G. Castro, G. Bernard, M. S. Rocha, G. G. Cerri, and N. L. Muller.** 1999. Chronic pulmonary paracoccidioidomycosis (South American blastomycosis): high-resolution CT findings in 41 patients. *Am. J. Roentgenol.* **173**:59–64.
118. **Gabriels, P., H. Joosen, E. Put, J. Verhaegen, K. Magerman, and R. Cartuyvels.** 2006. Recurrent *Rhodococcus equi* infection with fatal outcome in an immunocompetent patient. *Eur. J. Clin. Microbiol. Infect. Dis.* **25**:46–48.
119. **Gallant, J. E., and A. H. Ko.** 1996. Cavitary pulmonary lesions in patients infected with human immunodeficiency virus. *Clin. Infect. Dis.* **22**:671–682.
120. **Garthwaite, E. A., D. J. Border, C. H. Jones, and D. P. Worth.** 2007. *Rhodococcus equi* infection during treatment of a c-ANCA positive vasculitis: a case report. *Rheumatol. Int.* **27**:285–287.
121. **Gascon, J., J. M. Torres, M. Jimenez, T. Mejias, L. Trivino, F. Gobbi, L. Quinto, J. Puig, and M. Corachan.** 2005. Histoplasmosis infection in Spanish travelers to Latin America. *Eur. J. Clin. Microbiol. Infect. Dis.* **24**:839–841.
122. **Geffer, W. B., S. M. Albelda, G. H. Talbot, S. L. Gerson, P. A. Cassileth, and W. T. Miller.** 1985. Invasive pulmonary aspergillosis and acute leukemia. Limitations in the diagnostic utility of the air crescent sign. *Radiology* **157**:605–610.
123. **Geffer, W. B., T. R. Weingrad, D. M. Epstein, R. H. Ochs, and W. T. Miller.** 1981. "Semi-invasive" pulmonary aspergillosis: a new look at the spectrum of *Aspergillus* infections of the lung. *Radiology* **140**:313–321.
124. **Gillet, Y., P. Vanhems, G. Lina, M. Bes, F. Vandenesch, D. Floret, and J. Etienne.** 2007. Factors predicting mortality in necrotizing community-acquired pneumonia caused by *Staphylococcus aureus* containing Panton-Valentine leukocidin. *Clin. Infect. Dis.* **45**:315–321.
125. **Giraldo, R., A. Restrepo, F. Gutierrez, M. Robledo, F. Londono, H. Hernandez, F. Sierra, and G. Calle.** 1976. Pathogenesis of paracoccidioidomycosis: a model based on the study of 46 patients. *Mycopathologia* **58**:63–70.
126. **Gluck, T., H. F. Geerdes-Fenge, R. H. Straub, M. Raffenberg, B. Lang, H. Lode, and J. Scholmerich.** 2000. *Pneumocystis carinii* pneumonia as a complication of immunosuppressive therapy. *Infection* **28**:227–230.
127. **Goldman, N. A., R. Knapp-Clevenger, T. Hays, and M. J. Manco-Johnson.** 2005. Lemierre's and Lemierre's-like syndromes in children: survival and thromboembolic outcomes. *Pediatrics* **116**:e543–e548.
128. **Goldman, A. S., L. R. Goldman, and D. A. Goldman.** 2005. What caused the epidemic of *Pneumocystis pneumonia* in European premature infants in the mid-20th century? *Pediatrics* **115**:e725–e736.
129. **Golub, J. E., S. Bur, W. A. Cronin, S. Gange, N. Baruch, G. W. Comstock, and R. E. Chaisson.** 2006. Delayed tuberculosis diagnosis and tuberculosis transmission. *Int. J. Tuberc. Lung Dis.* **10**:24–30.
130. **Gonzalez, B. E., K. G. Hulten, M. K. Dishop, L. B. Lamberth, W. A. Hammerman, E. O. Mason, Jr., and S. L. Kaplan.** 2005. Pulmonary manifestations in children with invasive community-acquired *Staphylococcus aureus* infection. *Clin. Infect. Dis.* **41**:583–590.
131. **Gordon, M. A., H. T. Banda, M. Gondwe, S. B. Gordon, M. J. Boeree, A. L. Walsh, J. E. Corkill, C. A. Hart, C. F. Gilks, and M. E. Molyneux.** 2002. Non-typhoidal *Salmonella* bacteraemia among HIV-infected Malawian adults: high mortality and frequent recrudescence. *AIDS* **16**:1633–1641.
132. **Gottstein, B., and J. Reichen.** 2002. Hydatid lung disease (echinococcosis/hydatidosis). *Clin. Chest Med.* **23**:397–408.
133. **Gray, K. J., N. French, E. Lugada, C. Wagera, and C. F. Gilks.** 2000. *Rhodococcus equi* and HIV-1 infection in Uganda. *J. Infect.* **41**:227–231.
134. **Greendyke, W. H., D. L. Resnick, and W. C. Harvey.** 1970. The varied roentgen manifestations of primary coccidioidomycosis. *Am. J. Roentgenol. Radium Ther. Nucl. Med.* **109**:491–499.
135. **Griffith, D. E.** 2002. Management of disease due to *Mycobacterium kansasii*. *Clin. Chest Med.* **23**:613–621.
136. **Griffith, D. E., T. Aksumit, B. A. Brown-Elliott, A. Catanzaro, C. Daley, F. Gordin, S. M. Holland, R. Horsburgh, G. Huitt, M. F. Iademarco, M. Iseman, K. Olivier, S. Ruoss, C. F. von Reyn, R. J. Wallace, Jr., and K. Winthrop.** 2007. An official ATS/IDSA statement: diagnosis, treatment, and prevention of nontuberculous mycobacterial diseases. *Am. J. Respir. Crit. Care Med.* **175**:367–416.
137. **Griffith, D. E., W. M. Girard, and R. J. Wallace, Jr.** 1993. Clinical features

- of pulmonary disease caused by rapidly growing mycobacteria. An analysis of 154 patients. *Am. Rev. Respir. Dis.* **147**:1271–1278.
138. Grimm, M. B., N. D. Cohen, N. M. Slovis, G. D. Mundy, J. R. Harrington, M. C. Libal, S. Takai, and R. J. Martens. 2007. Evaluation of fecal samples from mares as a source of *Rhodococcus equi* for their foals by use of quantitative bacteriologic culture and colony immunoblot analyses. *Am. J. Vet. Res.* **68**:63–71.
 139. Guarnera, E. A., A. Parra, L. Kamenetzky, G. Garcia, and A. Gutierrez. 2004. Cystic echinococcosis in Argentina: evolution of metacestode and clinical expression in various *Echinococcus granulosus* strains. *Acta Trop.* **92**:153–159.
 140. Hachem, R., D. Sumoza, H. Hanna, E. Girgawy, M. Munsell, and I. Raad. 2006. Clinical and radiologic predictors of invasive pulmonary aspergillosis in cancer patients: should the European Organization for Research and Treatment of Cancer/Mycosis Study Group (EORTC/MSG) criteria be revised? *Cancer* **106**:1581–1586.
 141. Hadjiliadis, D., A. Adlakha, and U. B. Prakash. 1999. Rapidly growing mycobacterial lung infection in association with esophageal disorders. *Mayo Clin. Proc.* **74**:45–51.
 142. Hadlock, F. P., S. K. Park, R. J. Awe, and M. Rivera. 1980. Unusual radiographic findings in adult pulmonary tuberculosis. *Am. J. Roentgenol.* **134**:1015–1018.
 143. Halvorsen, R. A., J. D. Duncan, D. F. Merten, H. A. Gallis, and C. E. Putman. 1984. Pulmonary blastomycosis: radiologic manifestations. *Radiology* **150**:1–5.
 144. Hammond, J. M., P. D. Potgieter, D. Hanslo, H. Scott, and D. Roditi. 1995. The etiology and antimicrobial susceptibility patterns of microorganisms in acute community-acquired lung abscess. *Chest* **108**:937–941.
 145. Han, D., K. S. Lee, T. Franquet, N. L. Muller, T. S. Kim, H. Kim, O. J. Kwon, and H. S. Byun. 2003. Thrombotic and nonthrombotic pulmonary arterial embolism: spectrum of imaging findings. *Radiographics* **23**:1521–1539.
 146. Han, D., K. S. Lee, W. J. Koh, C. A. Yi, T. S. Kim, and O. J. Kwon. 2003. Radiographic and CT findings of nontuberculous mycobacterial pulmonary infection caused by *Mycobacterium abscessus*. *Am. J. Roentgenol.* **181**:513–517.
 147. Hanak, V., S. Kalra, T. R. Aksamit, T. E. Hartman, H. D. Tazelaar, and J. H. Ryu. 2006. Hot tub lung: presenting features and clinical course of 21 patients. *Respir. Med.* **100**:610–615.
 148. He, H., M. W. Stein, B. Zalta, and L. B. Haramati. 2006. Pulmonary infarction: spectrum of findings on multidetector helical CT. *J. Thorac. Imaging* **21**:1–7.
 149. Henriques, B., S. E. Hoffner, B. Petrini, I. Juhlin, P. Wahlen, and G. Kallenius. 1994. Infection with *Mycobacterium malmoense* in Sweden: report of 221 cases. *Clin. Infect. Dis.* **18**:596–600.
 150. Heussel, C. P., H. U. Kauczor, G. E. Heussel, B. Fischer, M. Begrich, P. Mildenerberger, and M. Thelen. 1999. Pneumonia in febrile neutropenic patients and in bone marrow and blood stem-cell transplant recipients: use of high-resolution computed tomography. *J. Clin. Oncol.* **17**:796–805.
 151. Hidalgo, A., V. Falco, S. Mauleon, J. Andreu, M. Crespo, E. Ribera, A. Pahissa, and J. Caceres. 2003. Accuracy of high-resolution CT in distinguishing between *Pneumocystis carinii* pneumonia and non-*Pneumocystis carinii* pneumonia in AIDS patients. *Eur. Radiol.* **13**:1179–1184.
 152. Hoban, D. J., D. J. Biedenbach, A. H. Mutnick, and R. N. Jones. 2003. Pathogen of occurrence and susceptibility patterns associated with pneumonia in hospitalized patients in North America: results of the SENTRY Antimicrobial Surveillance Study (2000). *Diagn. Microbiol. Infect. Dis.* **45**:279–285.
 153. Hodina, M., S. Hanquinet, J. Cotting, P. Schnyder, and F. Gudinchet. 2002. Imaging of cavitory necrosis in complicated childhood pneumonia. *Eur. Radiol.* **12**:391–396.
 154. Hollings, N. P., A. U. Wells, R. Wilson, and D. M. Hansell. 2002. Comparative appearances of non-tuberculous mycobacteria species: a CT study. *Eur. Radiol.* **12**:2211–2217.
 155. Holm, P. 1951. Studies on the aetiology of human actinomycosis. II. Do the other microbes of actinomycosis possess virulence? *Acta Pathol. Microbiol. Scand.* **28**:391–406.
 156. Horger, M., H. Hebart, H. Einsele, C. Lengerke, C. D. Claussen, R. Vonthein, and C. Pfannenberger. 2005. Initial CT manifestations of invasive pulmonary aspergillosis in 45 non-HIV immunocompromised patients: association with patient outcome? *Eur. J. Radiol.* **55**:437–444.
 157. Huang, J. H., P. N. Kao, V. Adi, and S. J. Ruoss. 1999. *Mycobacterium avium*-intracellular pulmonary infection in HIV-negative patients without preexisting lung disease: diagnostic and management limitations. *Chest* **115**:1033–1040.
 158. Huang, R. M., D. P. Naidich, E. Lubat, R. Schinella, S. M. Garay, and D. I. McCauley. 1989. Septic pulmonary emboli: CT-radiographic correlation. *Am. J. Roentgenol.* **153**:41–45.
 159. Hui, C. H., V. W. Au, K. Rowland, J. P. Slavotinek, and D. L. Gordon. 2003. Pulmonary nocardiosis re-visited: experience of 35 patients at diagnosis. *Respir. Med.* **97**:709–717.
 160. Hyde, L. 1958. Coccidioidal pulmonary cavitation. *Am. J. Med.* **25**:890–897.
 161. Iikuni, N., M. Kitahama, S. Ohta, H. Okamoto, N. Kamatani, and M. Nishinariita. 2006. Evaluation of *Pneumocystis pneumonia* infection risk factors in patients with connective tissue disease. *Mod. Rheumatol.* **16**:282–288.
 162. Im, J. G., H. Itoh, Y. S. Shim, J. H. Lee, J. Ahn, M. C. Han, and S. Noma. 1993. Pulmonary tuberculosis: CT findings—early active disease and sequential change with antituberculous therapy. *Radiology* **186**:653–660.
 163. Im, J. G., H. Y. Whang, W. S. Kim, M. C. Han, Y. S. Shim, and S. Y. Cho. 1992. Pleuropulmonary paragonimiasis: radiologic findings in 71 patients. *Am. J. Roentgenol.* **159**:39–43.
 164. Inglis, T. J., D. B. Rolim, and A. Q. Sousa. 2006. Melioidosis in the Americas. *Am. J. Trop. Med. Hyg.* **75**:947–954.
 165. Ip, M., L. G. Osterberg, P. Y. Chau, and T. A. Raffin. 1995. Pulmonary melioidosis. *Chest* **108**:1420–1424.
 166. Iwasaki, Y., K. Nagata, M. Nakanishi, A. Natuhara, H. Harada, Y. Kubota, I. Yokomura, S. Hashimoto, and M. Nakagawa. 2001. Spiral CT findings in septic pulmonary emboli. *Eur. J. Radiol.* **37**:190–194.
 167. Jamadar, D. A., E. A. Kazerooni, B. D. Daly, C. S. White, and B. H. Gross. 1995. Pulmonary zygomycosis: CT appearance. *J. Comput. Assist. Tomogr.* **19**:733–738.
 168. Jayanetra, P., P. Nitiyanant, L. Ajello, A. A. Padhye, S. Lolekha, V. Atichartakarn, P. Vathesatogit, B. Sathaphatayavongs, and R. Prajaktam. 1984. Penicilliosis marneffi in Thailand: report of five human cases. *Am. J. Trop. Med. Hyg.* **33**:637–644.
 169. Jenkins, P. A., and I. A. Campbell. 2003. Pulmonary disease caused by *Mycobacterium xenopi* in HIV-negative patients: five year follow-up of patients receiving standardised treatment. *Respir. Med.* **97**:439–444.
 170. Jeon, K., W. J. Koh, H. Kim, O. J. Kwon, T. S. Kim, K. S. Lee, and J. Han. 2005. Clinical features of recently diagnosed pulmonary paragonimiasis in Korea. *Chest* **128**:1423–1430.
 171. Johnson, R. J., and J. R. Johnson. 1983. Paragonimiasis in Indo-Chinese refugees. Roentgenographic findings with clinical correlations. *Am. Rev. Respir. Dis.* **128**:534–538.
 172. Jolles, H., P. L. Moseley, and M. W. Peterson. 1989. Nodular pulmonary opacities in patients with rheumatoid arthritis. A diagnostic dilemma. *Chest* **96**:1022–1025.
 173. Jones, P. D., and J. See. 1992. Penicillium marneffi infection in patients infected with human immunodeficiency virus: late presentation in an area of nonendemicity. *Clin. Infect. Dis.* **15**:744.
 174. Kalyoncu, U., O. Karadag, A. Akdogan, B. Kisacik, M. Erman, S. Erguven, and A. I. Ertenli. 2007. *Pneumocystis carinii* pneumonia in a rheumatoid arthritis patient treated with adalimumab. *Scand. J. Infect. Dis.* **39**:475–478.
 175. Kamboj, M., and K. A. Sepkowitz. 2006. The risk of tuberculosis in patients with cancer. *Clin. Infect. Dis.* **42**:1592–1595.
 176. Kang, E. Y., C. A. Staples, G. McGuinness, S. L. Primack, and N. L. Muller. 1996. Detection and differential diagnosis of pulmonary infections and tumors in patients with AIDS: value of chest radiography versus CT. *Am. J. Roentgenol.* **166**:15–19.
 177. Kaplan, W., and M. K. Clifford. 1964. Blastomycosis. I. A review of 198 collected cases in veterans administration hospitals. *Am. Rev. Respir. Dis.* **89**:659–672.
 178. Kapotsis, G. E., Z. Daniil, K. Malagari, C. Vamvouka, I. Kalomenidis, C. Roussos, and S. A. Papiiris. 2004. A young male with chest pain, cough and fever. *Eur. Respir. J.* **24**:506–509.
 179. Kaur, N., and T. C. Mahl. 2007. *Pneumocystis jirovecii* (carinii) pneumonia after infliximab therapy: a review of 84 cases. *Dig. Dis. Sci.* **52**:1481–1484.
 180. Keane, J., S. Gershon, R. P. Wise, E. Mirabile-Levens, J. Kasznica, W. D. Schwiertman, J. N. Siegel, and M. M. Braun. 2001. Tuberculosis associated with infliximab, a tumor necrosis factor alpha-neutralizing agent. *N. Engl. J. Med.* **345**:1098–1104.
 181. Kedlaya, L., M. B. Ing, and S. S. Wong. 2001. *Rhodococcus equi* infections in immunocompetent hosts: case report and review. *Clin. Infect. Dis.* **32**:E39–E46.
 182. Kennedy, C. C., and A. H. Limper. 2007. Redefining the clinical spectrum of chronic pulmonary histoplasmosis: a retrospective case series of 46 patients. *Medicine (Baltimore)* **86**:252–258.
 183. Kerbiriou, L., A. Ustianowski, M. A. Johnson, S. H. Gillespie, R. F. Miller, and M. C. Lipman. 2003. Human immunodeficiency virus type 1-related pulmonary *Mycobacterium xenopi* infection: a need to treat? *Clin. Infect. Dis.* **37**:1250–1254.
 184. Kerem, E., Z. Y. Bar, B. Rudenski, S. Katz, D. Kleid, and D. Branski. 1994. Bacteremic necrotizing pneumococcal pneumonia in children. *Am. J. Respir. Crit. Care Med.* **149**:242–244.
 185. Khazeni, N., R. J. Homer, A. N. Rubinowitz, and G. L. Chupp. 2006. Massive cavitary pulmonary rheumatoid nodules in a patient with HIV. *Eur. Respir. J.* **28**:872–874.
 186. Khor, A., K. O. Leslie, H. D. Tazelaar, R. A. Helmers, and T. V. Colby. 2001. Diffuse pulmonary disease caused by nontuberculous mycobacteria in immunocompetent people (hot tub lung). *Am. J. Clin. Pathol.* **115**:755–762.
 187. Khoury, M. B., J. D. Godwin, C. E. Ravin, H. A. Gallis, R. A. Halvorsen, and C. E. Putman. 1984. Thoracic cryptococcosis: immunologic competence and radiologic appearance. *Am. J. Roentgenol.* **142**:893–896.

188. Kim, S. J., Y. P. Hong, W. J. Lew, S. C. Yang, and E. G. Lee. 1995. Incidence of pulmonary tuberculosis among diabetics. *Tuber. Lung Dis.* **76**:529-533.
189. Kim, T. S., J. Han, S. S. Shim, K. Jeon, W. J. Koh, I. Lee, K. S. Lee, and O. J. Kwon. 2005. Pleuropulmonary paragonimiasis: CT findings in 31 patients. *Am. J. Roentgenol.* **185**:616-621.
190. Kim, Y. I., J. M. Goo, H. Y. Kim, J. W. Song, and J. G. Im. 2001. Coexisting bronchogenic carcinoma and pulmonary tuberculosis in the same lobe: radiologic findings and clinical significance. *Korean J. Radiol.* **2**:138-144.
191. Kirschner, R. A., Jr., B. C. Parker, and J. O. Falkinham III. 1992. Epidemiology of infection by nontuberculous mycobacteria. *Mycobacterium avium*, *Mycobacterium intracellulare*, and *Mycobacterium scrofulaceum* in acid, brown-water swamps of the southeastern United States and their association with environmental variables. *Am. Rev. Respir. Dis.* **145**:271-275.
192. Kishi, K., S. Homma, A. Kurosaki, T. Kohno, N. Motoi, and K. Yoshimura. 2006. Clinical features and high-resolution CT findings of pulmonary cryptococcosis in non-AIDS patients. *Respir. Med.* **100**:807-812.
193. Klein, J. S., M. Warnock, W. R. Webb, and G. Gamsu. 1989. Cavitating and noncavitating granulomas in AIDS patients with *Pneumocystis pneumoniae*. *Am. J. Roentgenol.* **152**:753-754.
194. Kobashi, Y., M. Fukuda, K. Yoshida, N. Miyashita, and M. Oka. 2006. Pulmonary *Mycobacterium intracellulare* disease with a solitary pulmonary nodule detected at the onset of pneumothorax. *J. Infect. Chemother.* **12**:203-206.
195. Koh, W. J., J. H. Lee, Y. S. Kwon, K. S. Lee, G. Y. Suh, M. P. Chung, H. Kim, and O. J. Kwon. 2007. Prevalence of gastroesophageal reflux disease in patients with nontuberculous mycobacterial lung disease. *Chest* **131**:1825-1830.
196. Kolodziejcki, L. S., S. Dyczek, K. Duda, J. Goralczyk, W. M. Wysocki, and W. Lobziewicz. 2003. Cavitated tumor as a clinical subtensity in squamous cell lung cancer patients. *Neoplasma* **50**:66-73.
197. Kontoyiannis, D. P., W. K. Peitsch, B. T. Reddy, E. E. Whimbey, X. Y. Han, G. P. Bodey, and K. V. Rolston. 2001. Cryptococcosis in patients with cancer. *Clin. Infect. Dis.* **32**:E145-E150.
198. Koponen, M. A., D. Zlock, D. L. Palmer, and T. L. Merlin. 1991. Melioidosis. Forgotten, but not gone! *Arch. Intern. Med.* **151**:605-608.
199. Korvick, J. A., A. K. Hackett, V. L. Yu, and R. R. Muder. 1991. Klebsiella pneumoniae in the modern era: clinicoradiographic correlations. *South. Med. J.* **84**:200-204.
200. Kovacs, J. A., J. W. Hiemenz, A. M. Macher, D. Stover, H. W. Murray, J. Shelhamer, H. C. Lane, C. Urmacher, C. Honig, D. L. Longo, et al. 1984. *Pneumocystis carinii* pneumonia: a comparison between patients with the acquired immunodeficiency syndrome and patients with other immunodeficiencies. *Ann. Intern. Med.* **100**:663-671.
201. Kuhlman, J. E., E. K. Fishman, P. A. Burch, J. E. Karp, E. A. Zerhouni, and S. S. Siegelman. 1987. Invasive pulmonary aspergillosis in acute leukemia. The contribution of CT to early diagnosis and aggressive management. *Chest* **92**:95-99.
202. Kuhlman, J. E., E. K. Fishman, and C. Teigen. 1990. Pulmonary septic emboli: diagnosis with CT. *Radiology* **174**:211-213.
203. Kuhlman, J. E., R. H. Hruban, and E. K. Fishman. 1991. Wegener granulomatosis: CT features of parenchymal lung disease. *J. Comput. Assist. Tomogr.* **15**:948-952.
204. Kumar, V., A. K. Abbas, N. Fausto, S. L. Robbins, and R. S. Cotran. 2005. Robbins and Cotran pathologic basis of disease. Elsevier Saunders, Philadelphia, PA.
205. Kwak, E. J., D. C. Strollo, S. M. Kulich, and S. Kusne. 2003. Cavitary pneumonia due to *Rhodococcus equi* in a heart transplant recipient. *Transpl. Infect. Dis.* **5**:43-46.
206. Kwong, J. S., N. L. Muller, J. D. Godwin, D. Aberle, and M. R. Grymaloski. 1992. Thoracic actinomycosis: CT findings in eight patients. *Radiology* **183**:189-192.
207. Lai, C. H., C. K. Huang, C. Chin, Y. T. Yang, H. F. Lin, and H. H. Lin. 2007. Indigenous case of disseminated histoplasmosis, Taiwan. *Emerg. Infect. Dis.* **13**:127-129.
208. Lai, K. K. 1990. Pulmonary Kaposi's sarcoma presenting as diffuse reticular nodular infiltrates with cavitary lesions. *South. Med. J.* **83**:1096-1098.
209. Le, T. H., N. Van De, D. Blair, D. P. McManus, H. Kino, and T. Agatsuma. 2006. Paragonimus heterotremus Chen and Hsia (1964), in Vietnam: a molecular identification and relationships of isolates from different hosts and geographical origins. *Acta Trop.* **98**:25-33.
210. Leake, J. A., D. G. Mosley, B. England, J. V. Graham, B. D. Plikaytis, N. M. Ampel, B. A. Perkins, and R. A. Hajjeh. 2000. Risk factors for acute symptomatic coccidioidomycosis among elderly persons in Arizona, 1996-1997. *J. Infect. Dis.* **181**:1435-1440.
211. Lee, F. Y., S. B. Mossad, and K. A. Adal. 1999. Pulmonary mucormycosis: the last 30 years. *Arch. Intern. Med.* **159**:1301-1309.
212. Lee, K. H., J. S. Lee, D. A. Lynch, K. S. Song, and T. H. Lim. 2002. The radiologic differential diagnosis of diffuse lung diseases characterized by multiple cysts or cavities. *J. Comput. Assist. Tomogr.* **26**:5-12.
213. Lee, K. S., T. S. Kim, K. Fujimoto, H. Moriya, H. Watanabe, U. Tateishi, K. Ashizawa, T. Johkoh, E. A. Kim, and O. J. Kwon. 2003. Thoracic manifestation of Wegener's granulomatosis: CT findings in 30 patients. *Eur. Radiol.* **13**:43-51.
214. Lee, K. S., P. Kullnig, T. E. Hartman, and N. L. Muller. 1994. Cryptogenic organizing pneumonia: CT findings in 43 patients. *Am. J. Roentgenol.* **162**:543-546.
215. Liao, W. Y., Y. S. Liaw, H. C. Wang, K. Y. Chen, K. T. Luh, and P. C. Yang. 2000. Bacteriology of infected cavitating lung tumor. *Am. J. Respir. Crit. Care Med.* **161**:1750-1753.
216. Libanore, M., E. Prini, M. Mazzetti, E. Barchi, E. Raise, F. M. Gritti, L. Bonazzi, and F. Ghinelli. 2002. Invasive aspergillosis in Italian AIDS patients. *Infection* **30**:341-345.
217. Libby, L. S., T. E. King, F. M. LaForce, and M. I. Schwarz. 1985. Pulmonary cavitation following pulmonary infarction. *Medicine (Baltimore)* **64**:342-348.
218. Lindell, R. M., T. E. Hartman, H. F. Nadrous, and J. H. Ryu. 2005. Pulmonary cryptococcosis: CT findings in immunocompetent patients. *Radiology* **236**:326-331.
219. Lo, C. Y., D. T. Chan, K. Y. Yuen, F. K. Li, and K. P. Cheng. 1995. *Penicillium marneffei* infection in a patient with SLE. *Lupus* **4**:229-231.
220. Logan, P. M., and N. L. Muller. 1996. CT manifestations of pulmonary aspergillosis. *Crit. Rev. Diagn. Imaging* **37**:1-37.
221. Londero, A. T., and C. D. Ramos. 1972. Paracoccidioidomycosis. A clinical and mycologic study of forty-one cases observed in Santa Maria, RS, Brazil. *Am. J. Med.* **52**:771-775.
222. Long, R., B. Maycher, M. Scalcini, and J. Manfreda. 1991. The chest roentgenogram in pulmonary tuberculosis patients seropositive for human immunodeficiency virus type 1. *Chest* **99**:123-127.
223. Lortholary, O., J. L. Mainardi, B. La Scola, V. Gallais, P. Frenaux, and P. Casassus. 2000. Consecutive bacillary angiomatosis and *Rhodococcus equi* bacteremia during acute leukemia: zoonoses may cause fever in neutropenic patients. *Clin. Microbiol. Infect.* **6**:334-336.
224. Lynch, D. A., P. M. Simone, M. A. Fox, B. L. Bucher, and M. J. Heinig. 1995. CT features of pulmonary *Mycobacterium avium* complex infection. *J. Comput. Assist. Tomogr.* **19**:353-360.
225. Mabeza, G. F., and J. Macfarlane. 2003. Pulmonary actinomycosis. *Eur. Respir. J.* **21**:545-551.
226. Macfarlane, J. 1994. An overview of community acquired pneumonia with lessons learned from the British Thoracic Society Study. *Semin. Respir. Infect.* **9**:153-165.
227. Macfarlane, J., and D. Rose. 1996. Radiographic features of staphylococcal pneumonia in adults and children. *Thorax* **51**:539-540.
228. MacMillan, J. C., S. H. Milstein, and P. C. Samson. 1978. Clinical spectrum of septic pulmonary embolism and infarction. *J. Thorac. Cardiovasc. Surg.* **75**:670-679.
229. Majano, V. L. 1957. Treatment of pulmonary hydatidosis. *Chest* **32**:93-96.
230. Maliwan, N., and J. R. Zvetina. 2005. Clinical features and follow up of 302 patients with *Mycobacterium kansasii* pulmonary infection: a 50 year experience. *Postgrad. Med. J.* **81**:530-533.
231. Manfredi, R., A. Nanetti, S. Morelli, M. Ferri, R. Valentini, L. Calza, and F. Chiodo. 2004. A decade surveillance study of *Mycobacterium xenopi* disease and antimicrobial susceptibility levels in a reference teaching hospital of northern Italy: HIV-associated versus non-HIV-associated infection. *HIV Clin. Trials* **5**:206-215.
232. Maniar, J. K., A. R. Chitale, A. Miskeen, K. Shah, and A. Maniar. 2005. *Penicillium marneffei* infection: an AIDS-defining illness. *Indian J. Dermatol. Venereol. Leprol.* **71**:202-204.
233. Marchiori, E., N. L. Muller, R. G. de Mendonca, D. Capone, A. S. Souza, Jr., D. L. Escuissato, E. L. Gasparotto, and E. M. de Cerqueira. 2005. *Rhodococcus equi* pneumonia in AIDS: high-resolution CT findings in five patients. *Br. J. Radiol.* **78**:783-786.
234. Mari, B., C. Monton, D. Mariscal, M. Lujan, M. Sala, and C. Domingo. 2001. Pulmonary nocardiosis: clinical experience in ten cases. *Respiration* **68**:382-388.
235. Martinez, R. C., V. M. Bonnin, A. C. Simon, F. A. Palacin, Z. J. Puig, and L. Sampablo. 2004. Primary pulmonary lymphoma presenting as a pulmonary mass with cavitation. *Arch. Bronconeumol.* **40**:94-96.
236. Maskell, G. F., C. M. Lockwood, and C. D. Flower. 1993. Computed tomography of the lung in Wegener's granulomatosis. *Clin. Radiol.* **48**:377-380.
237. Mathis, G. 1997. Thoraxsonography—part I: chest wall and pleura. *Ultrasound Med. Biol.* **23**:1131-1139.
238. McAdams, H. P., J. Erasmus, and J. A. Winter. 1995. Radiologic manifestations of pulmonary tuberculosis. *Radiol. Clin. N. Am.* **33**:655-678.
239. McAdams, H. P., D. C. Rosado, D. C. Strollo, and E. F. Patz, Jr. 1997. Pulmonary mucormycosis: radiologic findings in 32 cases. *Am. J. Roentgenol.* **168**:1541-1548.
240. McCloskey, M., M. Catherwood, D. McManus, G. Todd, R. Cuthbert, and M. Riley. 2004. A case of lymphomatoid granulomatosis masquerading as a lung abscess. *Thorax* **59**:818-819.
241. McGahan, J. P., D. S. Graves, P. E. Palmer, R. C. Stadalnik, and A. B. Dublin. 1981. Classic and contemporary imaging of coccidioidomycosis. *Am. J. Roentgenol.* **136**:393-404.

242. McManus, D. P., W. Zhang, J. Li, and P. B. Bartley. 2003. Echinococcosis. *Lancet* **362**:1295–1304.
243. Meersseman, W., S. J. Vandecasteele, A. Wilmer, E. Verbeken, W. E. Peetermans, and E. Van Wijngaerden. 2004. Invasive aspergillosis in critically ill patients without malignancy. *Am. J. Respir. Crit. Care Med.* **170**: 621–625.
244. Menendez, R., P. J. Cordero, M. Santos, M. Gobernado, and V. Marco. 1997. Pulmonary infection with *Nocardia* species: a report of 10 cases and review. *Eur. Respir. J.* **10**:1542–1546.
245. Michael, J. S., O. C. Abraham, D. Mathai, and M. S. Mathews. 2005. Varied clinical manifestations of *Penicillium marneffii* in patients with human immunodeficiency virus: a report from south India. *Mycoses* **48**: 120–121.
246. Miller, R. F., A. R. Lindley, A. Copas, H. E. Ambrose, R. J. Davies, and A. E. Wakefield. 2005. Genotypic variation in *Pneumocystis jirovecii* isolates in Britain. *Thorax* **60**:679–682.
247. Miller, R. R., and D. H. McGregor. 1980. Hemorrhage from carcinoma of the lung. *Cancer* **46**:200–205.
248. Miller, W. T., and R. R. MacGregor. 1978. Tuberculosis: frequency of unusual radiographic findings. *Am. J. Roentgenol.* **130**:867–875.
249. Miller, W. T., Jr., J. M. Edelman, and W. T. Miller. 1990. Cryptococcal pulmonary infection in patients with AIDS: radiographic appearance. *Radiology* **175**:725–728.
250. Mitchell, T. G., and J. R. Perfect. 1995. Cryptococcosis in the era of AIDS—100 years after the discovery of *Cryptococcus neoformans*. *Clin. Microbiol. Rev.* **8**:515–548.
251. Miura, H., O. Taira, S. Hiraguri, M. Hagiwara, and H. Kato. 1998. Cavitating adenocarcinoma of the lung. *Ann. Thorac. Cardiovasc. Surg.* **4**:154–158.
252. Montoya, J. G., S. V. Chaparro, D. Celis, J. A. Cortes, A. N. Leung, R. C. Robbins, and D. A. Stevens. 2003. Invasive aspergillosis in the setting of cardiac transplantation. *Clin. Infect. Dis.* **37**(Suppl. 3):S281–S292.
253. Montoya, J. G., L. F. Giraldo, B. Efron, E. B. Stinson, P. Gamberg, S. Hunt, N. Giannetti, J. Miller, and J. S. Remington. 2001. Infectious complications among 620 consecutive heart transplant patients at Stanford University Medical Center. *Clin. Infect. Dis.* **33**:629–640.
254. Moon, W. K., J. G. Im, K. M. Yeon, and M. C. Han. 1995. Complications of *Klebsiella pneumoniae*: CT evaluation. *J. Comput. Assist. Tomogr.* **19**:176–181.
255. Moore, A. D., J. D. Godwin, N. L. Muller, D. P. Naidich, S. P. Hammar, D. L. Buschman, J. E. Takasugi, and C. R. de Carvalho. 1989. Pulmonary histiocytosis X: comparison of radiographic and CT findings. *Radiology* **172**:249–254.
256. Mootsikapun, P., and S. Srikulbutr. 2006. Histoplasmosis and penicilliosis: comparison of clinical features, laboratory findings and outcome. *Int. J. Infect. Dis.* **10**:66–71.
257. Morgan, J., K. A. Wannemuehler, K. A. Marr, S. Hadley, D. P. Kontoyiannis, T. J. Walsh, S. K. Fridkin, P. G. Pappas, and D. W. Warnock. 2005. Incidence of invasive aspergillosis following hematopoietic stem cell and solid organ transplantation: interim results of a prospective multicenter surveillance program. *Med. Mycol.* **43**(Suppl. 1):S49–S58.
258. Morgenthaler, T. I., J. H. Ryu, and J. P. Utz. 1995. Cavitary pulmonary infarct in immunocompromised hosts. *Mayo Clin. Proc.* **70**:66–68.
259. Morris, A., J. D. Lundgren, H. Masur, P. D. Walzer, D. L. Hanson, T. Frederick, L. Huang, C. B. Beard, and J. E. Kaplan. 2004. Current epidemiology of *Pneumocystis pneumonia*. *Emerg. Infect. Dis.* **10**:1713–1720.
260. Moser, K. M. 1990. Venous thromboembolism. *Am. Rev. Respir. Dis.* **141**:235–249.
261. Mouroux, J., B. Padovani, D. Elkaim, and H. Richelme. 1996. Should cavitated bronchopulmonary cancers be considered a separate entity? *Ann. Thorac. Surg.* **61**:530–532.
262. Mukadi, Y., J. H. Perriens, M. E. St. Louis, C. Brown, J. Prignon, J. C. Willame, F. Pouthier, M. Kaboto, R. W. Ryder, F. Portaels, et al. 1993. Spectrum of immunodeficiency in HIV-1-infected patients with pulmonary tuberculosis in Zaire. *Lancet* **342**:143–146.
263. Mukae, H., H. Taniguchi, N. Matsumoto, H. Iiboshi, J. Ashitani, S. Matsukura, and Y. Nawa. 2001. Clinicoradiologic features of pleuropulmonary *Paragonimus westermani* on Kyusyu Island, Japan. *Chest* **120**:514–520.
264. Mukhopadhyay, A., K. H. Lee, and P. A. Tambyah. 2004. Bacteraemic melioidosis pneumonia: impact on outcome, clinical and radiological features. *J. Infect.* **48**:334–338.
265. Muller, N. L. 2002. Computed tomography and magnetic resonance imaging: past, present and future. *Eur. Respir. J. Suppl.* **35**:3s–12s.
266. Muller, N. L., P. Kullnig, and R. R. Miller. 1989. The CT findings of pulmonary sarcoidosis: analysis of 25 patients. *Am. J. Roentgenol.* **152**: 1179–1182.
267. Munoz, J., B. Mirelis, L. M. Aragon, N. Gutierrez, F. Sanchez, M. Espanol, O. Esparcia, M. Gurgui, P. Domingo, and P. Coll. 2007. Clinical and microbiological features of nocardiosis 1997–2003. *J. Med. Microbiol.* **56**: 545–550.
268. Munoz, P., A. Burillo, J. Palomo, M. Rodriguez-Creixems, and E. Bouza. 1998. *Rhodococcus equi* infection in transplant recipients: case report and review of the literature. *Transplantation* **65**:449–453.
269. Munoz, P., M. Marin, P. Tornero, R. P. Martin, M. Rodriguez-Creixems, and E. Bouza. 2000. Successful outcome of *Scedosporium apiospermum* disseminated infection treated with voriconazole in a patient receiving corticosteroid therapy. *Clin. Infect. Dis.* **31**:1499–1501.
270. Muntaner, L., M. Leyes, A. Payeras, M. Herrera, and A. Gutierrez. 1997. Radiologic features of *Rhodococcus equi* pneumonia in AIDS. *Eur. J. Radiol.* **24**:66–70.
271. Murayama, S., S. Sakai, H. Soeda, H. Yabuuchi, K. Masuda, H. Inoue, H. Watanabe, and Y. Matsuo. 2004. Pulmonary cryptococcosis in immunocompetent patients: HRCT characteristics. *Clin. Imaging* **28**:191–195.
272. Murphy, J., P. Schnyder, C. Herold, and C. Flower. 1998. Bronchiolitis obliterans organising pneumonia simulating bronchial carcinoma. *Eur. Radiol.* **8**:1165–1169.
273. Murray, J. F., S. M. Finegold, S. Froman, and D. W. Will. 1961. The changing spectrum of nocardiosis. A review and presentation of nine cases. *Am. Rev. Respir. Dis.* **83**:315–330.
274. Muscatello, G., G. A. Anderson, J. R. Gilkerson, and G. F. Browning. 2006. Associations between the ecology of virulent *Rhodococcus equi* and the epidemiology of *R. equi* pneumonia on Australian thoroughbred farms. *Appl. Environ. Microbiol.* **72**:6152–6160.
275. Mylonakis, E., T. F. Barlam, T. Flanagan, and J. D. Rich. 1998. Pulmonary aspergillosis and invasive disease in AIDS: review of 342 cases. *Chest* **114**:251–262.
276. Nadrous, H. F., V. S. Antonios, C. L. Terrell, and J. H. Ryu. 2003. Pulmonary cryptococcosis in nonimmunocompromised patients. *Chest* **124**:2143–2147.
277. Ng, G. W., W. Cheuk, M. K. Lee, T. C. Wu, and K. F. Chau. 2006. Test and teach. Fever and disseminated lymphadenopathy in a SLE patient in Hong Kong. Diagnosis: penicilliosis. *Pathology (Philadelphia)* **38**:353–355.
278. Nuesch, R., C. Bellini, and W. Zimmerli. 1999. *Pneumocystis carinii* pneumonia in human immunodeficiency virus (HIV)-positive and HIV-negative immunocompromised patients. *Clin. Infect. Dis.* **29**:1519–1523.
279. Nyamande, K., U. G. Laloo, and F. Vawda. 2007. Comparison of plain chest radiography and high-resolution CT in human immunodeficiency virus infected patients with community-acquired pneumonia: a sub-Saharan Africa study. *Br. J. Radiol.* **80**:302–306.
280. Odell, J. A., S. Alvarez, D. G. Cvitkovich, D. A. Cortese, and B. L. McComb. 2000. Multiple lung abscesses due to *Ochroconis gallopavum*, a dematiaceous fungus, in a nonimmunocompromised wood pulp worker. *Chest* **118**: 1503–1505.
281. O'Donnell, A. E., and L. S. Pappas. 1988. Pulmonary complications of intravenous drug abuse. Experience at an inner-city hospital. *Chest* **94**:251–253.
282. Ogakwu, M., and C. Nwokolo. 1973. Radiological findings in pulmonary paragonimiasis as seen in Nigeria: a review based on one hundred cases. *Br. J. Radiol.* **46**:699–705.
283. Onn, A., D. H. Choe, R. S. Herbst, A. M. Correa, R. F. Munden, M. T. Truong, A. A. Vaporciyan, T. Isobe, M. Z. Gilcrease, and E. M. Marom. 2005. Tumor cavitation in stage I non-small cell lung cancer: epidermal growth factor receptor expression and prediction of poor outcome. *Radiology* **237**:342–347.
284. Opravil, M., B. Marinček, W. A. Fuchs, R. Weber, R. Speich, M. Battagay, E. W. Russi, and R. Luthy. 1994. Shortcomings of chest radiography in detecting *Pneumocystis carinii* pneumonia. *J. Acquir. Immune Defic. Syndr.* **7**:39–45.
285. Padhye, A. A., L. Kaufman, E. Durry, C. K. Banerjee, S. K. Jindal, P. Talwar, and A. Chakrabarti. 1992. Fatal pulmonary sporotrichosis caused by *Sporothrix schenckii* var. *luriei* in India. *J. Clin. Microbiol.* **30**:2492–2494.
286. Paganin, F., F. Lilienthal, A. Bourdin, N. Lugagne, F. Tixier, R. Genin, and J. L. Yvin. 2004. Severe community-acquired pneumonia: assessment of microbial aetiology as mortality factor. *Eur. Respir. J.* **24**:779–785.
287. Pagano, L., L. Fianchi, C. Caramatti, D. D'Antonio, L. Melillo, M. Caira, L. Masini, G. Todeschini, C. Girmenia, B. Martino, S. Cinieri, P. Martino, and A. Del Favero. 2004. Cryptococcosis in patients with hematologic malignancies. A report from GIMEMA-Infection. *Haematologica* **89**:852–856.
288. Pagano, L., L. Fianchi, L. Mele, C. Girmenia, M. Offidani, P. Ricci, M. E. Mitra, M. Picardi, C. Caramatti, P. Piccaluga, A. Nosari, M. Buelli, B. Allione, A. Cortelezzi, F. Fabbiano, G. Milone, R. Invernizzi, B. Martino, L. Masini, G. Todeschini, M. A. Cappucci, D. Russo, L. Corvatta, P. Martino, and A. Del Favero. 2002. *Pneumocystis carinii* pneumonia in patients with malignant hematological diseases: 10 years' experience of infection in GIMEMA centres. *Br. J. Haematol.* **117**:379–386.
289. Park, B. J., K. Sigel, V. Vaz, K. Komatsu, C. McRill, M. Phelan, T. Colman, A. C. Comrie, D. W. Warnock, J. N. Galgiani, and R. A. Hajjeh. 2005. An epidemic of coccidioidomycosis in Arizona associated with climatic changes, 1998–2001. *J. Infect. Dis.* **191**:1981–1987.
290. Park, Y., T. S. Kim, C. A. Yi, E. Y. Cho, H. Kim, and Y. S. Choi. 2007. Pulmonary cavitary mass containing a mural nodule: differential diagnosis

- between intracavitary aspergilloma and cavitating lung cancer on contrast-enhanced computed tomography. *Clin. Radiol.* **62**:227–232.
291. **Parker, B. C., M. A. Ford, H. Gruft, and J. O. Falkinham III.** 1983. Epidemiology of infection by nontuberculous mycobacteria. IV. Preferential aerosolization of *Mycobacterium* intracellularly from natural waters. *Am. Rev. Respir. Dis.* **128**:652–656.
 292. **Pasmans, H. L., O. J. Loosveld, H. C. Schouten, F. Thunnissen, and J. M. van Engelshoven.** 1992. Invasive aspergillosis in immunocompromised patients: findings on plain film and (HR)CT. *Eur. J. Radiol.* **14**:37–40.
 293. **Patel, R. G., B. Patel, M. F. Petrini, R. R. Carter III, and J. Griffith.** 1999. Clinical presentation, radiographic findings, and diagnostic methods of pulmonary blastomycosis: a review of 100 consecutive cases. *South. Med. J.* **92**:289–295.
 294. **Patel, S., A. E. Parsyan, J. Gunn, M. A. Barry, C. Reed, S. Sharnprapai, and C. R. Horsburgh, Jr.** 2007. Risk of progression to active tuberculosis among foreign-born persons with latent tuberculosis. *Chest* **131**:1811–1816.
 295. **Peleg, A. Y., S. Husain, Z. A. Qureshi, F. P. Silveira, M. Sarumi, K. A. Shutt, E. J. Kwak, and D. L. Paterson.** 2007. Risk factors, clinical characteristics, and outcome of *Nocardia* infection in organ transplant recipients: a matched case-control study. *Clin. Infect. Dis.* **44**:1307–1314.
 296. **Penner, C., B. Maycher, and R. Long.** 1994. Pulmonary gangrene. A complication of bacterial pneumonia. *Chest* **105**:567–573.
 297. **Perez, M. G., T. Vassilev, and S. A. Kemmerly.** 2002. *Rhodococcus equi* infection in transplant recipients: a case of mistaken identity and review of the literature. *Transpl. Infect. Dis.* **4**:52–56.
 298. **Perez-Guzman, C., A. Torres-Cruz, H. Villarreal-Velarde, M. A. Salazar-Lezama, and M. H. Vargas.** 2001. Atypical radiological images of pulmonary tuberculosis in 192 diabetic patients: a comparative study. *Int. J. Tuberc. Lung Dis.* **5**:455–461.
 299. **Perfect, J. R., G. M. Cox, J. Y. Lee, C. A. Kauffman, L. de Repentigny, S. W. Chapman, V. A. Morrison, P. Pappas, J. W. Hiemenz, and D. A. Stevens.** 2001. The impact of culture isolation of *Aspergillus* species: a hospital-based survey of aspergillosis. *Clin. Infect. Dis.* **33**:1824–1833.
 300. **Perfect, J. R., D. T. Durack, and H. A. Gallis.** 1983. Cryptococemia. *Medicine (Baltimore)* **62**:98–109.
 301. **Pintado, V., E. Gomez-Mampaso, J. Fortun, M. A. Meseguer, J. Cobo, E. Navas, C. Quereda, P. Martin-Davila, and S. Moreno.** 2002. Infection with *Nocardia* species: clinical spectrum of disease and species distribution in Madrid, Spain, 1978–2001. *Infection* **30**:338–340.
 302. **Prince, D. S., D. D. Peterson, R. M. Steiner, J. E. Gottlieb, R. Scott, H. L. Israel, W. G. Figueroa, and J. E. Fish.** 1989. Infection with *Mycobacterium avium* complex in patients without predisposing conditions. *N. Engl. J. Med.* **321**:863–868.
 303. **Ramirez, J., R. P. Byrd, Jr., and T. M. Roy.** 1998. Chronic cavitary pulmonary sporotrichosis: efficacy of oral itraconazole. *J. Ky. Med. Assoc.* **96**:103–105.
 304. **Ramphul, N., K. M. Eastham, R. Freeman, G. Eltringham, A. M. Kearns, J. P. Leeming, A. Hasan, L. J. Hamilton, and D. A. Spencer.** 2006. Cavitary lung disease complicating empyema in children. *Pediatr. Pulmonol.* **41**:750–753.
 305. **Ray, P., M. Antoine, M. Mary-Krause, M. G. Lebrette, M. Wislez, C. Duvivier, M. C. Meyohas, P. M. Girard, C. Mayaud, and J. Cadranel.** 1998. AIDS-related primary pulmonary lymphoma. *Am. J. Respir. Crit. Care Med.* **158**:1221–1229.
 306. **Recht, L. D., J. R. Phillips, M. R. Eckman, and G. A. Sarosi.** 1979. Self-limited blastomycosis: a report of thirteen cases. *Am. Rev. Respir. Dis.* **120**:1109–1112.
 307. **Regnard, J. F., P. Icard, M. Nicolosi, L. Spagiari, P. Magdeleinat, B. Jauffret, and P. Levasseur.** 2000. Aspergilloma: a series of 89 surgical cases. *Ann. Thorac. Surg.* **69**:898–903.
 308. **Reichenberger, F., J. M. Habicht, A. Gratwohl, and M. Tamm.** 2002. Diagnosis and treatment of invasive pulmonary aspergillosis in neutropenic patients. *Eur. Respir. J.* **19**:743–755.
 309. **Research Committee of the British Thoracic and Tuberculosis Association.** 1970. Aspergilloma and residual tuberculous cavities—the results of a resurvey. *Tubercle* **51**:227–245.
 310. **Restrepo, A., M. E. Salazar, L. E. Cano, E. P. Stover, D. Feldman, and D. A. Stevens.** 1984. Estrogens inhibit mycelium-to-yeast transformation in the fungus *Paracoccidioides brasiliensis*: implications for resistance of females to paracoccidioidomycosis. *Infect. Immun.* **46**:346–353.
 311. **Rimek, D., T. Zimmermann, M. Hartmann, C. Prariyachitigul, and R. Kappe.** 1999. Disseminated *Penicillium marneffii* infection in an HIV-positive female from Thailand in Germany. *Mycoses* **42**(Suppl. 2):25–28.
 312. **Robbins, A. W., and N. S. Arora.** 1981. Pulmonary cavitation caused by *Haemophilus influenzae* in adults. *South. Med. J.* **74**:225–227.
 313. **Roblot, F., C. Godet, G. Le Moal, B. Garo, S. M. Faouzi, M. Dary, L. De Gentile, J. A. Gandji, Y. Guimard, C. Lacroix, P. Roblot, and B. Becq-Giraudon.** 2002. Analysis of underlying diseases and prognosis factors associated with *Pneumocystis pneumonia* in immunocompromised HIV-negative patients. *Eur. J. Clin. Microbiol. Infect. Dis.* **21**:523–531.
 314. **Roden, M. M., T. E. Zautis, W. L. Buchanan, T. A. Knudsen, T. A. Sarkisova, R. L. Schaufele, M. Sein, T. Sein, C. C. Chiou, J. H. Chu, D. P. Kontoyiannis, and T. J. Walsh.** 2005. Epidemiology and outcome of zygomycosis: a review of 929 reported cases. *Clin. Infect. Dis.* **41**:634–653.
 315. **Rodrigo, T., J. A. Cayla, P. Garcia de Olalla, H. Galdos-Tanguis, J. M. Jansa, P. Miranda, and T. Brugal.** 1997. Characteristics of tuberculosis patients who generate secondary cases. *Int. J. Tuberc. Lung Dis.* **1**:352–357.
 316. **Roebuck, D. J., D. A. Fisher, and B. J. Currie.** 1998. Cryptococcosis in HIV negative patients: findings on chest radiography. *Thorax* **53**:554–557.
 317. **Romig, T., W. Kratzer, P. Kimmig, M. Frosch, W. Gaus, W. A. Flegel, B. Gottstein, R. Lucius, K. Beckh, and P. Kern, et al.** 1999. An epidemiologic survey of human alveolar echinococcosis in southwestern Germany. *Am. J. Trop. Med. Hyg.* **61**:566–573.
 318. **Rooney, G., M. R. Nelson, and B. Gazzard.** 1996. *Mycobacterium kansasii*: its presentation, treatment and outcome in HIV infected patients. *J. Clin. Pathol.* **49**:821–823.
 319. **Rosenow, E., C. V. Strimlan, J. R. Muhm, and R. H. Ferguson.** 1977. Pleuropulmonary manifestations of ankylosing spondylitis. *Mayo Clin. Proc.* **52**:641–649.
 320. **Rosenstein, N. E., K. W. Emery, S. B. Werner, A. Kao, R. Johnson, D. Rogers, D. Vugia, A. Reingold, R. Talbot, B. D. Plikaytis, B. A. Perkins, and R. A. Hajjeh.** 2001. Risk factors for severe pulmonary and disseminated coccidioidomycosis: Kern County, California, 1995–1996. *Clin. Infect. Dis.* **32**:708–715.
 321. **Rosenzweig, D. Y.** 1979. Pulmonary mycobacterial infections due to *Mycobacterium intracellulare-avium* complex. Clinical features and course in 100 consecutive cases. *Chest* **75**:115–119.
 322. **Ryu, J. H., and S. J. Swensen.** 2003. Cystic and cavitary lung diseases: focal and diffuse. *Mayo Clin. Proc.* **78**:744–752.
 323. **Saadiah, S., A. H. Jeffrey, and A. L. Mohamed.** 1999. *Penicillium marneffii* infection in a non AIDS patient: first case report from Malaysia. *Med. J. Malaysia* **54**:264–266.
 324. **San Blas, G.** 1993. Paracoccidioidomycosis and its etiologic agent *Paracoccidioides brasiliensis*. *J. Med. Vet. Mycol.* **31**:99–113.
 325. **Sansom, H. E., M. Baque-Juston, A. U. Wells, and D. M. Hansell.** 2000. Lateral cavity wall thickening as an early radiographic sign of mycetoma formation. *Eur. Radiol.* **10**:387–390.
 326. **Santelli, A. C., J. E. Blair, and L. R. Roust.** 2006. Coccidioidomycosis in patients with diabetes mellitus. *Am. J. Med.* **119**:964–969.
 327. **Sarosi, G. A., and S. F. Davies.** 1979. Blastomycosis. *Am. Rev. Respir. Dis.* **120**:911–938.
 328. **Schueller, G., W. Matzek, P. Kalhs, and C. Schaefer-Prokop.** 2005. Pulmonary infections in the late period after allogeneic bone marrow transplantation: chest radiography versus computed tomography. *Eur. J. Radiol.* **53**:489–494.
 329. **Selwyn, P. A., A. S. Pumerantz, A. Durante, P. G. Alcibas, M. N. Gourevitch, P. M. Boisselle, and J. G. Elmore.** 1998. Clinical predictors of *Pneumocystis carinii* pneumonia, bacterial pneumonia and tuberculosis in HIV-infected patients. *AIDS* **12**:885–893.
 330. **Senocak, O., M. Manisali, D. Ozaksoy, C. Sevinc, and E. Akalin.** 2003. Lung parenchyma changes in ankylosing spondylitis: demonstration with high resolution CT and correlation with disease duration. *Eur. J. Radiol.* **45**:117–122.
 331. **Severo, L. C., F. M. Oliveira, K. Irion, N. S. Porto, and A. T. Londero.** 2001. Histoplasmosis in Rio Grande do Sul, Brazil: a 21-year experience. *Rev. Inst. Med. Trop. Sao Paulo* **43**:183–187.
 332. **Shah, R. M., S. Gupta, E. Angeid-Backman, and J. O'Donnell.** 2000. Pneumococcal pneumonia in patients requiring hospitalization: effects of bacteremia and HIV seropositivity on radiographic appearance. *Am. J. Roentgenol.* **175**:1533–1536.
 333. **Shambesh, M. A., P. S. Craig, C. N. MacPherson, M. T. Rogan, A. M. Gusbi, and E. F. Echuish.** 1999. An extensive ultrasound and serologic study to investigate the prevalence of human cystic echinococcosis in northern Libya. *Am. J. Trop. Med. Hyg.* **60**:462–468.
 334. **Shaukat, A., F. Bakri, P. Young, T. Hahn, D. Ball, M. R. Baer, M. Wetzler, J. L. Slack, P. Loud, M. Czuczman, P. L. McCarthy, T. J. Walsh, and B. H. Segal.** 2005. Invasive filamentous fungal infections in allogeneic hematopoietic stem cell transplant recipients after recovery from neutropenia: clinical, radiologic, and pathologic characteristics. *Mycopathologia* **159**:181–188.
 335. **Shefflin, J. R., J. A. Campbell, and G. P. Thompson.** 1990. Pulmonary blastomycosis: findings on chest radiographs in 63 patients. *Am. J. Roentgenol.* **154**:1177–1180.
 336. **Silva-Vergara, M. L., R. Martinez, A. Chadu, M. Madeira, G. Freitas-Silva, and C. M. Leite Maffei.** 1998. Isolation of a *Paracoccidioides brasiliensis* strain from the soil of a coffee plantation in Ibia, State of Minas Gerais, Brazil. *Med. Mycol.* **36**:37–42.
 337. **Simoes, L. B., S. A. Marques, and E. Bagagli.** 2004. Distribution of paracoccidioidomycosis: determination of ecologic correlates through spatial analyses. *Med. Mycol.* **42**:517–523.
 338. **Simor, A. E., I. E. Salit, and H. Vellend.** 1984. The role of *Mycobacterium xenopi* in human disease. *Am. Rev. Respir. Dis.* **129**:435–438.
 339. **Singh, N., R. K. Avery, P. Munoz, T. L. Pruett, B. Alexander, R. Jacobs, J. G. Tollemar, E. A. Dominguez, C. M. Yu, D. L. Paterson, S. Husain, S.**

- Kusne, and P. Linden. 2003. Trends in risk profiles for and mortality associated with invasive aspergillosis among liver transplant recipients. *Clin. Infect. Dis.* **36**:46–52.
340. Singh, P. N., K. Ranjana, Y. I. Singh, K. P. Singh, S. S. Sharma, M. Kulachandra, Y. Nabakumar, A. Chakrabarti, A. A. Padhye, L. Kaufman, and L. Ajello. 1999. Indigenous disseminated *Penicillium marneffei* infection in the state of Manipur, India: report of four autochthonous cases. *J. Clin. Microbiol.* **37**:2699–2702.
341. Smego, R. A., Jr., and G. Foglia. 1998. Actinomycosis. *Clin. Infect. Dis.* **26**:1255–1261.
342. Soubani, A. O., and P. H. Chandrasekar. 2002. The clinical spectrum of pulmonary aspergillosis. *Chest* **121**:1988–1999.
343. Soulamas, R., C. Danel, X. Chauffour, and M. Riquet. 2001. Lung cancer occurring with *Mycobacterium xenopi* and *Aspergillus*. *Eur. J. Cardiothorac. Surg.* **20**:211–213.
344. Souza, A. S., Jr., E. L. Gasparetto, T. Davaus, D. L. Escuissato, and E. Marchiori. 2006. High-resolution CT findings of 77 patients with untreated pulmonary paracoccidioidomycosis. *Am. J. Roentgenol.* **187**:1248–1252.
345. Stein, D. L., L. B. Haramati, H. Spindola-Franco, J. Friedman, and P. J. Klapper. 2005. Intrathoracic lymphadenopathy in hospitalized patients with pneumococcal pneumonia. *Chest* **127**:1271–1275.
346. Stelling, C. B., J. H. Woodring, S. R. Rehm, D. W. Hopper, and R. C. Noble. 1984. Miliary pulmonary blastomycosis. *Radiology* **150**:7–13.
347. Stout, J. E., K. K. Saharia, S. Nageswaran, A. Ahmed, and C. D. Hamilton. 2006. Racial and ethnic disparities in pediatric tuberculosis in North Carolina. *Arch. Pediatr. Adolesc. Med.* **160**:631–637.
348. Straus, D. C., D. L. Atkisson, and C. W. Garner. 1985. Importance of a lipopolysaccharide-containing extracellular toxic complex in infections produced by *Klebsiella pneumoniae*. *Inf. Immun.* **50**:787–795.
349. Sullivan, P. S., M. Denniston, A. McNaughten, S. E. Buskin, S. T. Broyles, and E. D. Mokotoff. 2007. Use of a population-based survey to determine incidence of AIDS-defining opportunistic illnesses among HIV-positive persons receiving medical care in the United States. *AIDS Res. Ther.* **4**:17.
350. Sun, H. Y., M. Y. Chen, C. F. Hsiao, S. M. Hsieh, C. C. Hung, and S. C. Chang. 2006. Endemic fungal infections caused by *Cryptococcus neoformans* and *Penicillium marneffei* in patients infected with human immunodeficiency virus and treated with highly active anti-retroviral therapy. *Clin. Microbiol. Infect.* **12**:381–388.
351. Supparatpinyo, K., S. Chiewchanvit, P. Hirunsri, C. Uthammachai, K. E. Nelson, and T. Sirisanthana. 1992. *Penicillium marneffei* infection in patients infected with human immunodeficiency virus. *Clin. Infect. Dis.* **14**:871–874.
352. Supparatpinyo, K., C. Khamwan, V. Baosoung, K. E. Nelson, and T. Sirisanthana. 1994. Disseminated *Penicillium marneffei* infection in south-east Asia. *Lancet* **344**:1110–1113.
353. Suputtamongkol, Y., W. Chaowagul, P. Chetchotisakd, N. Lertpatanasuwun, S. Intaranongpai, T. Ruchutrakool, D. Budhsarawong, P. Mootsikapun, V. Wuthiekanun, N. Teerawatsook, and A. Lulitanond. 1999. Risk factors for melioidosis and bacteremic melioidosis. *Clin. Infect. Dis.* **29**:408–413.
354. Suzuki, H., K. Matsui, T. Hirashima, M. Kobayashi, S. Sasada, N. Okamoto, N. Kitai, K. Kawahara, H. Fukuda, T. Komiya, and I. Kawase. 2006. Three cases of the nodular pulmonary amyloidosis with a long-term observation. *Intern. Med.* **45**:283–286.
355. Takai, S., S. Ohbushi, K. Koike, S. Tsubaki, H. Oishi, and M. Kamada. 1991. Prevalence of virulent *Rhodococcus equi* in isolates from soil and feces of horses from horse-breeding farms with and without endemic infections. *J. Clin. Microbiol.* **29**:2887–2889.
356. Tastepe, A. I., N. G. Ulasan, S. T. Liman, S. Demircan, and A. Uzar. 1998. Thoracic actinomycosis. *Eur. J. Cardiothorac. Surg.* **14**:578–583.
357. Tazi, A. 2006. Adult pulmonary Langerhans' cell histiocytosis. *Eur. Respir. J.* **27**:1272–1285.
358. Teel, K. W., M. D. Yow, and T. W. Williams, Jr. 1970. A localized outbreak of coccidioidomycosis in southern Texas. *J. Pediatr.* **77**:65–73.
359. Thomsen, V. O., A. B. Andersen, and H. Miorner. 2002. Incidence and clinical significance of non-tuberculous mycobacteria isolated from clinical specimens during a 2-y nationwide survey. *Scand. J. Infect. Dis.* **34**:648–653.
360. Thomson, R. M., J. G. Armstrong, and D. F. Looke. 2007. Gastroesophageal reflux disease, acid suppression, and *Mycobacterium avium* complex pulmonary disease. *Chest* **131**:1166–1172.
361. Thumler, J., and A. Munoz. 1978. Pulmonary and hepatic echinococcosis in children. *Pediatr. Radiol.* **7**:164–171.
362. Tobon, A. M., C. A. Agudelo, M. L. Osorio, D. L. Alvarez, M. Arango, L. E. Cano, and A. Restrepo. 2003. Residual pulmonary abnormalities in adult patients with chronic paracoccidioidomycosis: prolonged follow-up after itraconazole therapy. *Clin. Infect. Dis.* **37**:898–904.
363. Torres, H. A., R. F. Chemaly, R. Storey, E. A. Aguilera, G. M. Noguera, A. Salfard, K. V. Rolston, I. I. Raad, and D. P. Kontoyannis. 2006. Influence of type of cancer and hematopoietic stem cell transplantation on clinical presentation of *Pneumocystis jirovecii* pneumonia in cancer patients. *Eur. J. Clin. Microbiol. Infect. Dis.* **25**:382–388.
364. Torres-Tortosa, M., J. Arrizabalaga, J. L. Villanueva, J. Galvez, M. Leyes, M. E. Valencia, J. Flores, J. M. Pena, E. Perez-Cecilia, and C. Quereda. 2003. Prognosis and clinical evaluation of infection caused by *Rhodococcus equi* in HIV-infected patients: a multicenter study of 67 cases. *Chest* **123**:1970–1976.
365. Tortoli, E. 2003. Impact of genotypic studies on mycobacterial taxonomy: the new mycobacteria of the 1990s. *Clin. Microbiol. Rev.* **16**:319–354.
366. Tortoli, E., L. Rindi, M. J. Garcia, P. Chiaradonna, R. Dei, C. Garzelli, R. M. Kroppenstedt, N. Lari, R. Mattei, A. Mariottini, G. Mazzarelli, M. I. Murcia, A. Nanetti, P. Piccoli, and C. Scarparo. 2004. Proposal to elevate the genetic variant MAC-A, included in the *Mycobacterium avium* complex, to species rank as *Mycobacterium chimaera* sp. nov. *Int. J. Syst. Evol. Microbiol.* **54**:1277–1285.
367. Treugot, H., K. Schulze, K. H. Hubener, and R. Andrasch. 1980. Pulmonary involvement by *Echinococcus alveolaris*. *Radiology* **137**:37–41.
368. Tuddenham, W. J. 1984. Glossary of terms for thoracic radiology: recommendations of the Nomenclature Committee of the Fleischner Society. *Am. J. Roentgenol.* **143**:509–517.
369. Turetschek, K., W. Ebner, D. Fleischmann, P. Wunderbaldinger, L. Erlacher, T. Zontsich, and A. A. Bankier. 2000. Early pulmonary involvement in ankylosing spondylitis: assessment with thin-section CT. *Clin. Radiol.* **55**:632–636.
370. U.S. Cancer Statistics Working Group. 19 July 2007, accession date. United States Cancer Statistics: 1999–2003 incidence and mortality. Web-based report. Centers for Disease Control and Prevention, Atlanta, GA. www.cdc.gov/uscs.
371. Van Dyck, P., F. M. Vanhoenacker, P. Van den Brande, and A. M. De Schepper. 2003. Imaging of pulmonary tuberculosis. *Eur. Radiol.* **13**:1771–1785.
372. van Westerloo, D. J., S. Knapp, C. van't Veer, W. A. Buurman, A. F. de Vos, S. Florquin, and T. van der Poll. 2005. Aspiration pneumonitis primes the host for an exaggerated inflammatory response during pneumonia. *Crit. Care Med.* **33**:1770–1778.
373. Vargas, S. L., C. A. Ponce, F. Gigliotti, A. V. Ulloa, S. Prieto, M. P. Munoz, and W. T. Hughes. 2000. Transmission of *Pneumocystis carinii* DNA from a patient with *P. carinii* pneumonia to immunocompetent contact health care workers. *J. Clin. Microbiol.* **38**:1536–1538.
374. Vasquez, J. E., J. B. Mehta, R. Agrawal, and F. A. Sarubbi. 1998. Blastomycosis in northeast Tennessee. *Chest* **114**:436–443.
375. Velez, I. D., J. E. Ortega, and L. E. Velasquez. 2002. Paragonimiasis: a view from Columbia. *Clin. Chest Med.* **23**:421–431.
376. Verville, T. D., M. M. Huycke, R. A. Greenfield, D. P. Fine, T. L. Kuhls, and L. N. Slater. 1994. *Rhodococcus equi* infections of humans. 12 cases and a review of the literature. *Medicine (Baltimore)* **73**:119–132.
377. Vilchez, R. A., J. Fung, and S. Kusne. 2002. Cryptococcosis in organ transplant recipients: an overview. *Am. J. Transplant.* **2**:575–580.
378. Vogel, M. N., H. Brodoefel, T. Hierl, R. Beck, W. A. Bethge, C. D. Claussen, and M. S. Horgor. 2007. Differences and similarities of cytomegalovirus and pneumocystis pneumonia in HIV-negative immunocompromised patients—thin section CT morphology in the early phase of the disease. *Br. J. Radiol.* **80**:516–523.
379. Vogelaers, D., M. Petrovic, M. Deroo, P. Verplancke, Y. Claessens, J. M. Naeyaert, and M. Afschrift. 1997. A case of primary cutaneous cryptococcosis. *Eur. J. Clin. Microbiol. Infect. Dis.* **16**:150–152.
380. von Sinner, W. N. 1991. New diagnostic signs in hydatid disease; radiography, ultrasound, CT and MRI correlated to pathology. *Eur. J. Radiol.* **12**:150–159.
381. Wang, J. L., K. Y. Chen, C. T. Fang, P. R. Hsueh, P. C. Yang, and S. C. Chang. 2005. Changing bacteriology of adult community-acquired lung abscess in Taiwan: *Klebsiella pneumoniae* versus anaerobes. *Clin. Infect. Dis.* **40**:915–922.
382. Wang, J. Y., L. N. Lee, and P. R. Hsueh. 2005. Factors changing the manifestation of pulmonary tuberculosis. *Int. J. Tuberc. Lung Dis.* **9**:777–783.
383. Wang, T. L., J. S. Cheah, and K. Holmberg. 1996. Case report and review of disseminated histoplasmosis in South-East Asia: clinical and epidemiological implications. *Trop. Med. Int. Health* **1**:35–42.
384. Wasser, L., and W. Talavera. 1987. Pulmonary cryptococcosis in AIDS. *Chest* **92**:692–695.
385. Watanabe, H., S. Kobayashi, K. Watanabe, K. Oishi, T. Sanchai, W. Kositsakulchai, K. Kunsuikmengrai, S. Kahintapong, P. Tharavichitkul, T. Sirisanthana, and T. Nagatake. 2000. Pulmonary infection caused by *Rhodococcus equi* in HIV-infected patients: report of four patients from northern Thailand. *J. Infect. Chemother.* **6**:229–232.
386. Webb, W. R., and G. Gamsu. 1981. Cavitary pulmonary nodules with systemic lupus erythematosus: differential diagnosis. *Am. J. Roentgenol.* **136**:27–31.
387. Werner, S. B., D. Pappagianis, I. Heindl, and A. Mickel. 1972. An epidemic of coccidioidomycosis among archeology students in northern California. *N. Engl. J. Med.* **286**:507–512.
388. Wheat, L. J., T. G. Slama, H. E. Eitzen, R. B. Kohler, M. L. French, and J. L. Biesecker. 1981. A large urban outbreak of histoplasmosis: clinical features. *Ann. Intern. Med.* **94**:331–337.

389. **Wheat, L. J., J. Wass, J. Norton, R. B. Kohler, and M. L. French.** 1984. Cavitary histoplasmosis occurring during two large urban outbreaks. Analysis of clinical, epidemiologic, roentgenographic, and laboratory features. *Medicine (Baltimore)* **63**:201–209.
390. **Wicky, S., F. Cartei, B. Mayor, J. Frija, P. A. Gevenois, J. Giron, F. Laurent, G. Perri, and P. Schnyder.** 1996. Radiological findings in nine AIDS patients with *Rhodococcus equi* pneumonia. *Eur. Radiol.* **6**:826–830.
391. **Wilson, A. G., A. E. Joseph, and R. J. Butland.** 1986. The radiology of aseptic cavitation in pulmonary infarction. *Clin. Radiol.* **37**:327–333.
392. **Wilson, J. F., R. L. Rausch, and F. R. Wilson.** 1995. Alveolar hydatid disease. Review of the surgical experience in 42 cases of active disease among Alaskan Eskimos. *Ann. Surg.* **221**:315–323.
393. **Winer-Muram, H. T., and S. A. Rubin.** 1990. Thoracic complications of tuberculosis. *J. Thorac. Imaging* **5**:46–63.
394. **Winer-Muram, H. T., and S. A. Rubin.** 1992. Pulmonary blastomycosis. *J. Thorac. Imaging* **7**:23–28.
395. **Wittram, C., and G. L. Weisbrod.** 2002. *Mycobacterium avium* complex lung disease in immunocompetent patients: radiography-CT correlation. *Br. J. Radiol.* **75**:340–344.
396. **Wohl, A. R., P. Simon, Y. W. Hu, and J. S. Duchin.** 2002. The role of person-to-person transmission in an epidemiologic study of *Pneumocystis carinii* pneumonia. *AIDS* **16**:1821–1825.
397. **Wong, S. S., K. H. Wong, W. T. Hui, S. S. Lee, J. Y. Lo, L. Cao, and K. Y. Yuen.** 2001. Differences in clinical and laboratory diagnostic characteristics of penicilliosis marneffeii in human immunodeficiency virus (HIV)- and non-HIV-infected patients. *J. Clin. Microbiol.* **39**:4535–4540.
398. **Wong, S. S., P. C. Woo, and K. Y. Yuen.** 2001. *Candida tropicalis* and *Penicillium marneffeii* mixed fungaemia in a patient with Waldenstrom's macroglobulinaemia. *Eur. J. Clin. Microbiol. Infect. Dis.* **20**:132–135.
399. **Woodring, J. H., and A. M. Fried.** 1983. Significance of wall thickness in solitary cavities of the lung: a follow-up study. *Am. J. Roentgenol.* **140**:473–474.
400. **Woodring, J. H., A. M. Fried, and V. P. Chuang.** 1980. Solitary cavities of the lung: diagnostic implications of cavity wall thickness. *Am. J. Roentgenol.* **135**:1269–1271.
401. **Woodring, J. H., H. M. Vandiviere, A. M. Fried, M. L. Dillon, T. D. Williams, and I. G. Melvin.** 1986. Update: the radiographic features of pulmonary tuberculosis. *Am. J. Roentgenol.* **146**:497–506.
402. **Worsley, D. F., A. Alavi, J. M. Aronchick, J. T. Chen, R. H. Greenspan, and C. E. Ravin.** 1993. Chest radiographic findings in patients with acute pulmonary embolism: observations from the PIOPED Study. *Radiology* **189**:133–136.
403. **Wu, T. T., H. C. Wang, P. C. Yang, S. H. Kuo, and K. T. Luh.** 1999. Pulmonary cryptococcosis: manifestations in the era of acquired immunodeficiency syndrome. *J. Formos. Med. Assoc.* **98**:621–626.
404. **Yang, Y. W., Y. A. Kang, S. H. Lee, S. M. Lee, C. G. Yoo, Y. W. Kim, S. K. Han, Y. S. Shim, and J. J. Yim.** 2007. Aetiologies and predictors of pulmonary cavities in South Korea. *Int. J. Tuberc. Lung Dis.* **11**:457–462.
405. **Yangco, B. G., and S. C. Deresinski.** 1980. Necrotizing or cavitating pneumonia due to *Streptococcus pneumoniae*: report of four cases and review of the literature. *Medicine (Baltimore)* **59**:449–457.
406. **Yates, M. D., J. M. Grange, and C. H. Collins.** 1986. The nature of mycobacterial disease in south east England, 1977–84. *J. Epidemiol. Commun. Health* **40**:295–300.
407. **Yoon, H. K., J. G. Im, J. M. Ahn, and M. C. Han.** 1995. Pulmonary nocardiosis: CT findings. *J. Comput. Assist. Tomogr.* **19**:52–55.
408. **Yue, C. C., C. H. Park, and I. Kushner.** 1986. Apical fibrocavitary lesions of the lung in rheumatoid arthritis. Report of two cases and review of the literature. *Am. J. Med.* **81**:741–746.
409. **Zaas, D.** 2002. Cases from the Osler Medical Service at Johns Hopkins University. *Scedosporium apiospermum* mycetoma of the lung. *Am. J. Med.* **113**:760–762.
410. **Zahar, J. R., M. Robin, E. Azoulay, F. Fieux, G. Nitenberg, and B. Schlemmer.** 2002. *Pneumocystis carinii* pneumonia in critically ill patients with malignancy: a descriptive study. *Clin. Infect. Dis.* **35**:929–934.
411. **Zvetina, J. R., T. C. Demos, N. Maliwan, M. Van Drunen, W. Frederick, J. Lentino, and A. M. Modh.** 1984. Pulmonary cavitations in *Mycobacterium kansasii*: distinctions from *M. tuberculosis*. *Am. J. Roentgenol.* **143**:127–130.